



Delayed Encephalopathy of Carbon Monoxide Intoxication and Treatment with Hyperbaric Oxygen: A Case Report

Karbonmonoksit İntoksikasyonuna Bağlı Gecikmiş Ensefalopati ve Hiperbarik Oksijen Uygulaması: Olgu Sunumu

Fatma Polat, Nur Yüceyar, Ali Akay¹, Ayşe Sağduyu Kocaman

Ege University Medical Faculty, Department of Neurology, İzmir, Turkey

¹Ege University Medical Faculty, Department of Neurosurgery, İzmir, Turkey

Summary

Delayed encephalopathy (DE) is a neuropsychiatric syndrome that can generally arise within 20 days of acute carbon monoxide (CO) intoxication after apparent recovery and involves variable degrees of cognitive deficits, personality changes, movement disorders and focal neurologic deficits. We report a 35-year-old female patient with delayed encephalopathy due to CO intoxication, presenting with cognitive impairment and mild parkinsonism despite receiving hyperbaric oxygen therapy (HBO). Magnetic resonance imaging (MRI) showed abnormal signal intensity and decreased diffusivity at both caudate nuclei and globus pallidus. She continued to receive additional HBO therapy and completely recovered within six months. The positive effects of early HBO therapy in selected patients on reversing the acute effects of CO intoxication is apparent. Here we also review the beneficial effect of HBO in preventing or limiting the late neurocognitive deficits associated with severe CO intoxication. (*Turkish Journal of Neurology 2012; 18:118-22*)

Key Words: Carbon monoxide (CO), intoxication, delayed encephalopathy, magnetic resonance imaging (MRI), hyperbaric oxygen therapy (HBO)

Özet

Gecikmiş ensefalopati (GE) akut karbon monoksit (CO) intoksikasyonu ardından gözle görülür bir iyileşme periyodu ardından yaklaşık 20. günde gelişen farklı seviyelerde kognitif bozukluk, kişilik değişiklikleri, hareket bozuklukları ve fokal nörolojik bulguları içeren bir nöropsikiyatrik sendromdur. Hiperbarik oksijen tedavisi (HBO) uygulanmasına karşın CO intoksikasyonuna bağlı GE gelişen, kognitif bozukluk ve ılımlı parkinsonizm bulguları ile başvuran 35 yaşında kadın hasta sunulmaktadır. Kraniyal manyetik rezonans görüntüleme (MRG) her iki kaudat nükleus ve globus pallidusta anormal sinyal intensitesi ve difüzyon kısıtlaması saptanan hastada HBO tedavisine devam edilmiş ve 6 ay içinde tam iyileşme sağlanmıştır. Seçilmiş hastalarda CO intoksikasyonuna bağlı akut etkileri ortadan kaldırmak için erken dönemde uygulanan HBO tedavisinin olumlu etkisi aşikardır. Bu çalışmada ayrıca HBO tedavisinin, CO intoksikasyonuna bağlı GE gelişiminin önlenmesi veya sınırlandırılmasındaki yararı gözden geçirilecektir. (*Türk Nöroloji Dergisi 2012; 18:118-22*)

Anahtar Kelimeler: Karbon monoksit (CO), intoksikasyon, gecikmiş ensefalopati, manyetik rezonans görüntüleme (MRG), hiperbarik oksijen tedavisi (HBO)

Introduction

Carbon monoxide (CO) is an odorless, tasteless, colourless, non-irritant gas resulting from the burning of hydrocarbons. Toxic sources of CO include smoke inhalation, dysfunctioning heating systems such as water heaters, coal stoves, and motor vehicles in poorly ventilated areas. CO intoxication is a major cause of emergency room admissions and death from a toxic

cause (1,2). CO binds to hemoglobin with a higher affinity than oxygen, transforms into carboxyhemoglobin (COHb) and impairs oxygen transport and utilization. In addition, CO initiates the inflammatory cascade resulting in peroxidation of lipids and delayed neurologic sequelae in the central nervous system (CNS) (3,4). Morbidity related to CO intoxication is essentially associated with delayed neurocognitive impairment and may be seen at a rate of up to 40% in severely affected

Address for Correspondence/Yazışma Adresi: Fatma Polat MD, Ege University Medical Faculty, Department of Neurology, İzmir, Turkey

Phone.: +90 232 388 41 77 E-mail: drfpolat@hotmail.com

Received/Geliş Tarihi: 29.02.2012 **Accepted/Kabul Tarihi:** 23.08.2012

individuals. Severe delayed encephalopathy (LE) and cognitive sequelae are more rare, and were reported at a rate of 0.06%-11% in various series (5,6,7,8). Clinical picture consists of signs and symptoms of CNS impairment a few weeks after recovery from acute intoxication. While the pathophysiology is not completely clear yet, the underlying pathological lesion is believed to be the diffuse demyelination of the cerebral white matter (8).

In this article, we present a case of delayed encephalopathy developing after initial stabilization with magnetic resonance imaging (MRI), where hyperbaric oxygen therapy was administered following acute CO intoxication, as well as reviewing delayed neurological syndrome and hyperbaric oxygen therapy in the context of this case.

Case

A female patient of 35 years was brought to the emergency room 10 days ago after being found unconscious in the bathroom. Her arterial blood pressure was 110/60 mmHg, pulse rate was 128/minute, and respiratory rate was 30/minute at the emergency room. The patient's spatial, temporal and personal orientation was not well, and was initially diagnosed with intoxication from a malfunctioning water heater; her level of COHb measured with CO-oxymetry was found to be 27%. She was reported to be a non-smoker. Her arterial blood gases PO₂ and PH were within normal range. There was no pathology in the ECG and cardiac biomarkers, and a brain CT scan could not be performed due to the patient's agitated status. CO intoxication was suspected and 100% O₂ was administered via mask; the patient was discharged from the emergency room as her impaired consciousness improved almost completely within approximately 10-12 hours. Twelve (12) sessions of hyperbaric oxygen therapy was administered twice a day during the 6 days following her discharge, starting approximately 12 hours after the intoxication. After interrupting treatment for 2 days due to a holiday, she had to return to the emergency room with symptoms including headache, nausea, vomiting, forgetfulness, and abnormal behaviour. Her initial examination in the emergency room showed spatial – temporal disorientation, restriction in cooperation, and apathy. Her fundoscopic examination was normal. She was found to have mild parkinsonian signs including hypomimia, bradykinesia and mild decrease in associated movements. There was no pathology in other neurologic examination findings and CT scan. The cerebrospinal fluid, routine biochemical values, and viral - bacteriologic serology (HIV, hepatitis, Lyme disease etc) were within normal range. The patient was hospitalized with a preliminary diagnosis of encephalopathy. There was no pathology suggesting encephalopathy in the vasculitis markers, thyroid function tests and metabolic values. There was mild diffuse slowing in the electroencephalogram (EEG). Cranial MRG showed hyperintense lesions with no uptake of contrast

material in the FLAIR and T2A sections in both caudate nuclei and globus pallidus (Figures 1A-1B). Images consistent with diffusion restriction and vasogenic edema were seen in the same areas in diffusion-weighted imaging and apparent diffusion coefficient map sequences (Figures 2A-2B). The patient scored 46/59 in the short cognitive examination (SCE) test (Kayatekin 1985). There was no frontal dysfunction. Following clinical and ancillary assessments the patient was diagnosed with delayed CO encephalopathy, and continued her current hyperbaric oxygen therapy twice a day, for a total of 50 sessions. EEG findings had completely improved at the 3 month follow-up, and scored 52/59 in the SCE test. She was observed to have difficulty with the questions related to permanent memory. At the six month follow-up short cognitive examination and the verbal memory, visual memory test, naming test, clock drawing test, verbal fluency tests, stroop test, luria series, graphomotor series, and the test battery assessing functional activities were performed for a detailed evaluation of the patient's cognitive functions, and her performance was found to be normal.

Discussion

Acute carbon monoxide intoxication is diagnosed by suggestive history, physical examination and accompanying elevation of COHb level following CO-oxymetry measurement of venous blood sample (1,2). Standard pulse oxymetry is not helpful in assessment because carboxyhemoglobin cannot be distinguished from oxyhemoglobin. PO₂ value provides the O₂ value that is soluble in blood and this is not affected by CO. Similar to our case, PO₂ tends to be normal. The O₂ binding to hemoglobin is clearly low in the presence of COHb. COHb baseline values are 10-15% in smokers and 3% in non-smokers, and any value above these levels suggests intoxication. COHb level is not exactly in correlation with the degree of intoxication and is not predictive for the development of delayed encephalopathy (1,2). The COHb level in our case was found to be above normal in the acute stage, and her history and clinical examination supported the diagnosis of acute CO intoxication at her initial presentation to the emergency room.

CO may cause injury in numerous organs, especially the central nervous system and cardiovascular system, which use a high amount of oxygen. CO intoxication causes nonspecific symptoms including headache, irritability, visual impairment, dizziness, nausea and vomiting. These are usually accompanied by mental impairment varying from mild confusion to coma. Cardiovascular and metabolic complications including seizures, syncope, coma, myocardial ischemia, ventricular arrhythmia, pulmonary edema, and lactic acidosis are seen in severe CO toxicity. Acute myocardial damage is found to determine mortality in long-term follow-up. Cognitive disorders such as impairment in memory, attention, visual – spatial abilities and operational functions, dementia, apraxia, mood disorders, and personality changes can be seen following CO intoxication

(2,5,6,7,8). Our patient developed mental confusion during the acute CO intoxication stage, but there were no cardiac complaints or findings.

CO rapidly diffuses in the pulmonary capillary membrane. Its affinity to the iron in "hem" is 240-fold higher than that of oxygen. Once CO binds to hemoglobin, there is a decrease in the ability of binding sites carrying oxygen to peripheral tissues. This causes a left shift in the oxyhemoglobin dissociation curve and impairs delivery of oxygen in tissues. CO also affects peripheral oxygen utilization. Ten to 15% of CO is extravascular, and affects oxidative phosphorylation at the mitochondria level by binding to molecules including myoglobin, cytochromes, NADPH reductase. The half-life of this binding is longer than that of COHb. This effect outside the hemoglobin is shown mostly in the heart. Moreover, it can impair peripheral oxygen utilization by inactivating cytochrome oxidase (3,4).

CO intoxication causes neuropathological changes through other biochemical mechanisms. Suggested mechanisms include cellular hypoxia resulting from various intracellular proteins binding to CO, neurotoxicity through hypersecretion of

excitatory amino acids such as glutamate, neutrophil activation as a result of lipid peroxidation, endothelial accumulation of peroxynitrates causing damage in the blood vessel endothelium, and apoptosis or programmed cellular death (10,11,12,13,14,15).

Delayed encephalopathy is a clinical condition characterized by cognitive impairment of varying degrees, personality change, movement disorders and focal neurologic findings developing a few weeks after the initial improvement period in individuals severely exposed to CO. The interval varies between 3 days and 240 days (mean 20 days). Most frequent symptoms are mental impairment, incontinence, parkinsonism, gait disorder and mutism. Sequelae findings may persist for a year or even longer (5,6,7,8). Most cases have a history of loss of consciousness during the acute intoxication. Development of delayed encephalopathy is not directly proportional to the COHb level (16). Our patient was thought to have delayed encephalopathy resulting from CO intoxication due to her complete initial improvement after the CO intoxication, re-admittance to the emergency room 10 days later with encephalopathy and mild parkinsonism, and after excluding other causes of encephalopathy.

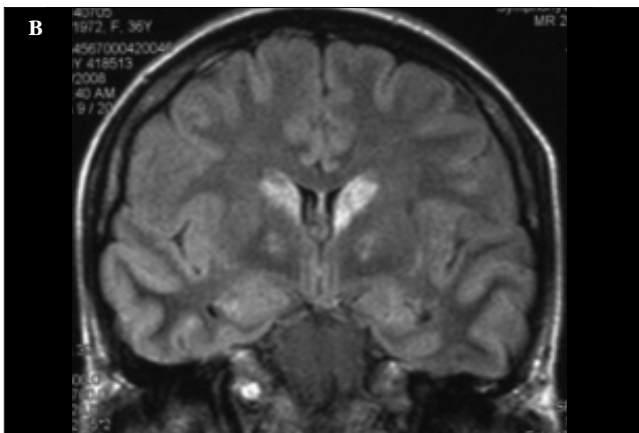
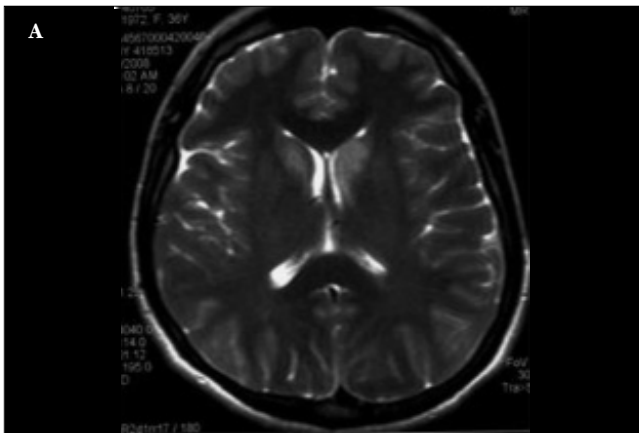


Figure 1a-b. Hyperintense lesions in both the caudate nuclei and globus pallidus, in FLAIR and T2A sections.

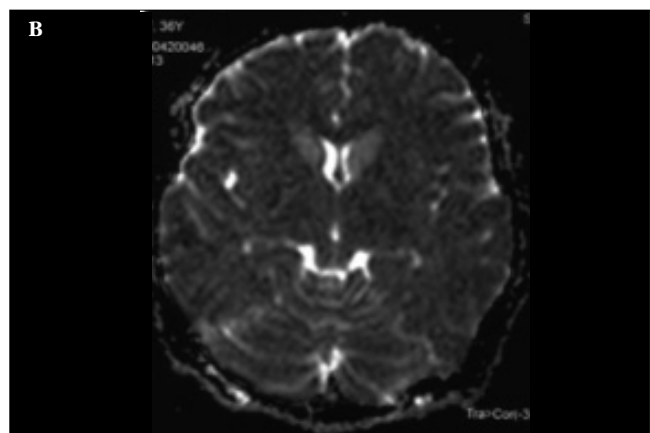
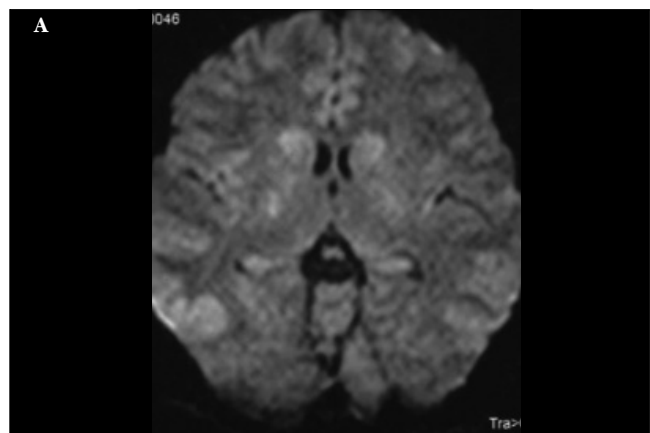


Figure 2a-b. Diffusion restriction and vasogenic edema in both caudate nuclei and globus pallidus in the DWI and ADC sequences.

Hemorrhagic infarct of the globus pallidus and deep white matter involvement have been reported following acute CO intoxication, albeit rarely (17). Findings of delayed encephalopathy resulting from CO intoxication were well defined with conventional MRI (2,8,18,19,20). T2-weighted imaging typically shows bilateral symmetric, high signal intensity in the basal ganglia, as well as the periventricular deep white matter and the semioval centrum. Our patient had hyperintense lesions in the T2-weighted sequences in both caudate nuclei and globus pallidus, as well as diffusion restriction in these lesions. Literature suggests that mechanisms such as cytotoxic / vasogenic edema secondary to acute myelinopathy and cellular energy deficiency or the accumulation of toxic biochemical products may be responsible for late-onset diffusion restriction (8,20). Diffusion restriction consistent with vasogenic edema was found in our patient in the DWI and ADC sequences.

In the retrospective examination of 198 patients developing delayed encephalopathy, 15% of the patients were reported to have basal ganglion involvement, 70% subcortical white matter involvement, whereas 12.6% of the patients had both lesions and 2.1% had no lesions. There was basal ganglion involvement in our case, but no white matter lesions. The period between the onset of the condition and the initial improvement varied between 7 and 44 days, 21 with an average of 21 days. This period is shorter (10 days) in our case. Absence of white matter involvement, presence of lesions in only the basal ganglia and the short period between the onset and initial improvement are notable features in our case. There are reports in literature, similar to our case, of delayed encephalopathy cases with a short interval, subacute onset and no white matter lesions (22).

Basal ganglion lesions can also be seen in CO intoxication. Literature suggests that the basal ganglion lesions encountered after CO intoxication are seen not only in the group developing delayed encephalopathy, but also in the group not developing delayed encephalopathy (23). Presence of basal ganglion lesions in our patient in addition to impairment in consciousness following an interval, supports the delayed encephalopathy diagnosis.

Impairment of oxygen distribution and usage may not be responsible in delayed encephalopathy as in DE. Based on MRI findings, it is thought that the underlying pathological lesion is the diffuse demyelination in cerebral white matter.⁸ However, the mechanism of DE is not yet fully explained. Some of the proposed theories are the direct toxic effect of CO, cerebral blood vessel damage, cerebral edema and hypersensitivity reaction (11,12,13,14,15). Lipid peroxidation caused by toxic oxygen molecules due to xanthine oxidase is also believed to be a potential cause. Xanthine oxidase is manufactured in situ from xanthine dehydrogenase by enzymes released from white blood cells adhering to damaged endothelial cells (2,11,12,13,14,15). Events analogue to ischemia – reperfusion damage in the improvement process following CO acute intoxication and

exposure to hyperoxia are suggested to increase the initial oxidative damage (2).

HBO therapy is among the treatment steps of CO intoxication, providing 100% O₂ inhalation in supra-atmospheric environment. CO is eliminated from pulmonary circulation by the competitive binding of oxygen to hemoglobin. Elimination depends on the degree of oxygenation and, in a lesser degree, to ventilation per minute (2,24). The half-life of COHb is 30 minutes when the patient is inhaling ambient room air; this time increases to 90 minutes with normobaric oxygen administration and decreases to 30 minutes with HBO. The amount of oxygen soluble in blood increases from 0.3 ml/dl to 0.6 ml/dl and more extra-hemoglobin oxygen is distributed to tissues. Patients who will potentially benefit from HBO therapy are clear acidosis with pH <7.1, myocardial ischemia, and those with organ ischemia findings including loss of consciousness.² HBO indication is, independent of clinical picture, found when COHb level is generally above 25%. However, differences exist between centers, despite general opinion. It is sometimes administered high-risk patients with lower levels.

HBO therapy may be useful in delayed neurocognitive deficits accompanying severe CO intoxication, providing benefit when started in the initial 6 hours following intoxication. Therapy started after 12 hours has not been proven beneficial (23). HBO therapy was administered to our patient approximately 12 hours after acute intoxication. The incidence and severity of DE were investigated in studies for the treatment of CO intoxication with varying quality and results among studies (5,25,26,27). Two noteworthy double-blind studies evaluating all cases, independent of the severity of intoxication, demonstrate differing results (25). In the 152 patient series where randomized, double-blind HBO and normobaric oxygen (NBO) therapy was administered within 24 hours, cognitive sequelae was higher 6 weeks later in patients receiving NBO, 25 whereas improvement was sustained at 1 year follow-up in patients receiving HBO. The other randomized, double-blind study did not report a positive response in the 191 patients receiving HBO therapy during 2 years; on the contrary, impairment in neuropsychiatric tests and delayed neurological sequelae were seen more at 1 month in the HBO group (26). In a different randomized controlled study, NBO and one session of HBO following NBO were compared in patients presenting with temporary loss of consciousness, and no clear difference was reported for complete neurocognitive improvement between the group receiving HBO and receiving NBO alone. Results were found to be worse in patients presenting with coma after 2 sessions of HBO versus 1 session of HBO (26). The above-mentioned studies have some methodological problems, including administering HBO therapy in low atmospheric pressure, varying severity of toxicity in patients receiving NBO and HBO, delay in treatment, and patients being lost to follow-up (27).

The prognosis of delayed encephalopathy due to CO intoxication is relatively well. One clinical study reports the improvement rate in patients at 1 year as 75%. However, sequelae including mild memory impairment and parkinsonism may persist. Levodopa and anticholinergic drugs are shown to be ineffective in parkinsonian symptom.² Our data shows clearly that HBO has a role in the treatment of acute intoxication, whereas its neuroprotective role is controversial. If events analogue to ischemia – reperfusion damage are indeed involved in the pathogenesis, hyperoxemia may even be potentially harmful. We may talk about the positive effect of the HBO therapy, considering DE development when HBO therapy was interrupted, and the rapid improvement period when sessions were resumed; if there was no benefit worsening in neurological sequelae would be expected. HBO could also be limiting the DE clinical syndrome, considering the good prognosis in spite of DE development following adequate HBO therapy. However, randomized prospective studies are needed for a definitive conclusion on the role of HBO in the development and treatment of DE.

References

- Ernst A, Zibrak JD. Carbon monoxide poisoning. *N Engl J Med* 1998;339:1603-8.
- Weaver LK. Carbon monoxide poisoning. *N Engl J Med* 2009;360:1217-25.
- Piantadosi CA. Carbon monoxide, oxygen transport and oxygen metabolism. *Journal of Hyperbaric Medicine* 1987;2:27-44.
- Hardy KR, Thom SR. Pathophysiology and treatment of carbon monoxide poisoning. *J Toxicol Clin Toxicol* 1994;32:613-29.
- Thom SR, Taber RL, Mendiguren II, Clark JM, Hardy KR, Fisher AB. Delayed neuropsychologic sequelae after carbon monoxide poisoning: prevention by treatment with hyperbaric oxygen. *Ann Emerg Med* 1995;25(4):474-80.
- Choi IS. Delayed neurologic sequelae in carbon monoxide intoxication. *Arch Neurol* 1983;40:433-5.
- Kwon OY, Chung SP, Ha YR, Yoo IS, Kim SW. Delayed postanoxic encephalopathy after carbon monoxide poisoning. *Emerg Med J* 2004;21:250-1.
- Kim JH, Chang KH, Song IC, Kim KH, Kwon BJ, Kim HC, et al. Delayed encephalopathy of acute carbon monoxide intoxication: diffusivity of cerebral white matter lesions. *AJNR Am J Neuroradiol* 2003;24:1592-7.
- Bozeman WP, Myers RA, Barish RA. Confirmation of the pulse oximetry gap in carbon monoxide poisoning. *Ann Emerg Med* 1997;30:608-11.
- Okeda R, Funata N, Takano T, Miyazaki Y, Higashino F, Yokoyama K, et al. The pathogenesis of carbon monoxide encephalopathy in the acute phase—physiological and morphological correlation. *Acta Neuropathol* 1981;54:1-10.
- Thom SR, Bhopale VM, Fisher D, Zhang J, Gimotty P. Delayed neuropathology after carbon monoxide poisoning is immune-mediated. *Proc Natl Acad Sci USA* 2004;101:13660-5.
- Zhang J, Piantadosi CA. Mitochondrial oxidative stress after carbon monoxide hypoxia in the rat brain. *J Clin Invest* 1992;90:1193-9.
- Thom SR. Carbon monoxide-mediated brain lipid peroxidation in the rat. *J Appl Physiol* 1990;68:997-1003.
- Thom SR, Xu YA, Ischiropoulos H. Vascular endothelial cells generate peroxynitrite in response to carbon monoxide exposure. *Chem Res Toxicol* 1997;10:1023-31.
- Piantadosi CA, Schmechel DE, Zhang J. Is neuronal degeneration mediated by apoptosis after carbon monoxide poisoning. *Undersea and Hyperbaric Medicine* 1995;22:15-6.
- Seger D, Welch L. Carbon monoxide controversies: neuropsychologic testing, mechanism of toxicity, and hyperbaric oxygen. *Ann Emerg Med* 1994;24:242-8.
- Finelli PF, DiMario FJ Jr. Hemorrhagic infarction in white matter following acute carbon monoxide poisoning. *Neurology* 2004;63:1102-4.
- Chang KH, Han MH, Kim HS, Wie BA, Han MC. Delayed encephalopathy after acute carbon monoxide intoxication: MR imaging features and distribution of cerebral white matter lesions. *Radiology* 1992;184:117-22.
- Zagami AS, Lethlean AK, Mellick R. Delayed neurological deterioration following carbon monoxide poisoning: MRI findings. *J Neurol* 1993;240:113-6.
- Teksam M, Casey SO, Michel E, Liu H, Truwit CL. Diffusion-weighted MR imaging findings in carbon monoxide poisoning. *Neuroradiology* 2002;44:109-13.
- Yu H, Pan X, Meng J, Ding J, Xu G, Fang G. A clinical study on delayed encephalopathy after carbon monoxide poisoning. *Zhonghua Lao Dong Wei Sheng Zhi Ye Bing Za Zhi* 2002;20:26-8.
- Erdal A, Kutlu G, Tunç T, İnan L. Karbonmonoksit İntoksikasyonuna bağlı geç ensefalopati: Olgu sunumu. *TJN* 2008;14:295-8.
- Otubo S, Shirakawa Y, Aibiki M, Nishiyama T, Maekawa S, Kikuchi K, et al. Magnetic resonance imaging could predict delayed encephalopathy after acute carbon monoxide intoxication. *Chudoku Kenkyu* 2007;20:253-61.
- Weaver LK, Hopkins RO, Chan KJ, Churchill S, Elliott CG, Clemmer TP, et al. Hyperbaric oxygen for acute carbon monoxide poisoning. *N Engl J Med* 2002;347:1057-67.
- Juurlink DN, Buckley NA, Stanbrook MB, Isbister GK, Bennett M, McGuigan MA. Hyperbaric oxygen for carbon monoxide poisoning. *Cochrane Database Syst Rev* 2005;(1):CD002041.
- Annane D, Chadha K, Gajdos P, Jars-Guincestre MC, Chevret S, Raphael JC. Hyperbaric oxygen therapy for acute domestic carbon monoxide poisoning: two randomized controlled trials. *Intensive Care Med* 2011;37:486-92.
- Buckley NA, Juurlink DN, Isbister G, Bennett MH, Lavonas EJ. Hyperbaric oxygen for carbon monoxide poisoning. *Cochrane Database Syst Rev* 2011;4:CD002041.