



## Neurosyphilis: Various Presentations

### *Nörosifiliz: Farklı Prezantasyonları*

Kezban Aslan, Hacer Bozdemir, Şebnem Bıçakçı, Turgay Demir, İlker Öztürk, Tamer Çelik\*

Çukurova University Faculty of Medicine, Department of Neurology, Adana, Turkey

\*Çukurova University Faculty of Medicine, Department of Child Neurology, Adana, Turkey

#### **Summary**

Neurosyphilis develops in about 5% of untreated patients infected with *Treponema pallidum*. The spirochete disseminates systemically hours to days after inoculation. Early invasion of the central nervous system can be seen in infected patients without symptoms. Here we present three patients with varying complaints, diagnosed with neurosyphilis during diagnostic work-up. The patients had diplopia, headache and blurred vision, numbness and thinning in the feet. (*Turkish Journal of Neurology* 2012; 18:168-172)

**Key Words:** Neurosyphilis, tonic pupilla, pseudotumour cerebri, polyneuropathy

#### **Özet**

Nörosifiliz, *Treponema pallidum* ile infekte olan olguların yaklaşık %5'inde gelişmektedir. Spiroketin, inokülasyondan birkaç saat veya birkaç gün sonra sistemik olarak yayılmaya başladığı bilinmektedir. Santral sinir sistemine erken invazyon, semptomatik olmasa da, sifiliz ile infekte olan bir çok hastada gözlenebilir. Burada farklı yakınmalar ile başvuran ve etyolojik incelemeleri yapıldığı sırada nörosifiliz tanısı almış üç hasta sunulmuştur. Olgular çift görme, baş ağrısı ve bulanık görme, ayaklarda uyuşma ve incelme yakınması ile başvurmuşlardır. (*Türk Nöroloji Dergisi* 2012; 18:168-172)

**Anahtar Kelimeler:** Nörosifiliz, tonik pupilla, psödo tümör serebri, polinöropati

#### **Introduction**

Syphliis is a venereal disease rarely seen in post-antibiotherapy era. However, in recent years, its prevalence was shown to rise in Europe and USA (1,2). Venereal infections including syphilis are reported to be on a marked rise with the increase in the prevalence of the human immune deficiency virus (HIV) infection (1,3).

Neurosyphilis develops in approximately 5% of cases infected with *Treponema pallidum* (3). As the clinical symptomatology of the disease includes a very wide spectrum and mimics a variety of conditions, the term "the great imitator" appears to be quite appropriate for syphilis (4). Neurological involvement may affect motor and sensory nerves, and may include ophthalmic and

auditory symptoms, cranial nerve paralysis and meningitis symptoms and signs, at any stage of the disease (3). Ocular signs of the disease are some of the most important markers of the central nervous system (CNS) involvement (3,4).

Here we discuss with facts from literature, three cases who presented with various signs and symptoms and later were diagnosed with neurosyphilis.

#### **Case**

##### **Case 1**

Forty-seven year old male patient presented with a complaint of double vision. He had no history of a systemic disease; he had

**Address for Correspondence / Yazışma Adresi:** Dr. Kezban Aslan, Çukurova University Faculty of Medicine, Department of Neurology, Adana, Turkey

Phone.: +90 322 338 60 60 E-mail: kezbanaslan@hotmail.com

**Received/Geliş Tarihi:** 27.05.2012 **Accepted/Kabul Tarihi:** 30.09.2012

been smoking 1 pack of cigarettes for 20 years. He reported double vision on outer gaze for the last five months and enlargement in his right pupil compared to the left one. His neuro-ophthalmologic examination showed that in a mid level illumination assessment and primary position the right pupil vs left pupil was 7 mm vs 4 mm, respectively; on the other hand, in the light, right pupil vs left pupil was 7 mm vs 3 mm, respectively. There was no tonic response, light response was slow in the left and absent in the right. Indirect light reflex in the right was (-), near reflex in the left was (+), near reflex in the right was (-), and optic disc was bilateral normal. Eyelids were normal, right saccadic eye movements were stepwise, he described diplopia with right lateral gaze and there was no bilateral optokinetic nistagmus. There was no motor deficit, deep tendon reflexes (DTRs) were bilateral normoactive, cerebellar tests were normal, Babinski response was (-/-), and vibration sense was found to be normal.

Blood chemistry and blood count were normal. Serum Venereal Disease Research Laboratory (VDRL) was 1/2 (+), *Treponema pallidum* hemagglutination (TPHA) 1/1280 was Dil (+), cerebrospinal fluid (CSF) VDRL was negative, and TPHA was 1/320 Dil (+); other infection tests were found to be negative in serum and CSF, and CSF chemistry showed glucose 70 mg/dL, lactate dehydrogenase (LDH) 43 U/L, sodium 148 mmol/L, protein 33.9 mg/dL, lactate 1.45 mmol/L, pH 8, density 1010 and no cells. The somatosensory evoked potential (SEP) was normal, visual evoked potential (VEP) P100 latency was normal bilaterally; however, there was decrease of amplitude in the left, and slow activity paroxysms occurring in the right temporoparieto-occipital areas HPV on the electroencephalogram (EEG). Orbital and cerebral magnetic resonance imaging (MRI) and angiogram were normal. Mild carpal tunnel syndrome signs were found on the left on the electromyogram – electroneurogram (EMG-ENG). Pilocarpine test was found to be positive.

#### Case 2

Forty-six year old female patient presented with complaints of headache and blurred vision. She explained that her complaints began 4-5 months ago with blunt headaches without photophobia of early morning onset, arising from the back of the neck and spreading throughout the head; although the headaches improved partly during the day, the baseline low-grade headache remained. She also reported that a short time after she began suffering from headaches, she started having blurred vision in both eyes, early in the morning, affecting the whole visual field and decreasing in time. She was hospitalized due to recent increase in headaches, and pain with eye movements. Her neurological examination showed that her pupils were isochoric, the light reflex was intact, papilla margins were not clear on funduscopic exam, the patient could count fingers blurrily at 5 meters, and other neurological findings were found to be normal. Blood chemistry and blood count were normal; lumbar puncture (LP) showed that CSF pressure was 28 cm. CSF chemistry results were, glucose 64 mg/dL, LDH 32 U/L, sodium 148 mmol/L, potassium 3 mmol/L, protein 30.8 mg/dL, lactate 1.7 mg/dL, pH

8, density 1010 and no cells. The serum results were VDRL 1/2 dil (+), TPHA 1/320 dil (+) (repeated twice), CSF results were VDRL 1/4 dil + and TPHA 1/320 +. Other infections test results in the serum and CSF were negative. There was mild slowing in the VEP in the right P100 latency (2.2 msec) compared to the left, but there was no amplitude asymmetry. Orbital MRI showed bilateral maxillar and ethmoidal sinusitis, hypervascular mass image consistent with a meningioma in the left frontal area, and pituitary MRI showed an extra-axial mass (consistent with meningioma) in the left frontal area.

MR angiogram and venogram showed that the sagittal, transvers, rectus and sigmoid sinuses and the internal jugular veins were patent, and there were no vascular anomalies. EMG-ENG examinations were normal. All hormone profiles, including thyroid function tests, were found to be normal.

The patient had an ob-gyn consultation because her VDRL and TPHA tests were found to be positive twice. After collecting vaginal smear, treatment was initiated with miconazole and metronidazole combination once a day as a vaginal suppository, benzathine penicillin 2.4 million units, once a day, and acetazolamide 250 mg, 3 times a day. Follow-up LP showed CSF pressure to be 14 cm. The patient was discharged with her headache and blurred vision complaints totally improved.

#### Case 3

Forty-four year old male patient presented with a complaint of numbness in his feet. His medical history showed that he had high blood pressure for 14 years, he had a lesion resembling a pimple in his genital area in 1995 but did not go to a doctor for this complaint, he's been having itchy, red and raised lesions on his hips and legs occasionally since 2006 and he's been diagnosed with syphilis in 2007 when he wanted to donate blood and had the required tests done. Penicillin treatment was recommended after the diagnosis, but he admitted to administering the treatment irregularly and inadequately. He reported that he's been having pains, numbness and tingling in both legs for the last ten years, and these complaints have been increasing and he's started having thinning and weakening in his feet in the last 2 years.

His neurological examination showed that pupils were isochoric, and the light reflex was intact; funduscopic exam was normal, conjugated eye movements and other cranial nerves, as well as the muscle strength in upper extremities were found to be normal. Muscle strength in the lower extremities was bilateral symmetrical, dorsal flexion 4/5 in the feet, DTR were positive four ways, with hypoesthesia at right L4-5; sensation of vibration was diminished in the lower extremities and sensation of position was normal. Difficulty in heel gait and clear bilateral peroneal atrophy on the right side were observed.

Blood chemistry, blood count, and thyroid function tests were normal. RPR was (+), VDRL 1/4 (+), TPHA 1/640 (+) (follow-up repeat test was positive, too); CSF examination could not be done because the patient did not accept it. EMG-ENG examination showed signs of polyneuropathy with involvement of sensory nerves (Table 1). Echocardiogram showed left ventricle relaxing

impairment, atheromatous changes in the aorta, whereas cerebral MRI with contrast showed nonspecific milimetric signal increase in the left frontal and rear parietal fields. Lumbosacral spinal MRI showed a large surface disc bulging compressing the dural sac at the L4-S1 level, and an annular tear posterior to the disc at the L4-L5 level.

## Discussion

It is well known that *Treponema pallidum*, the agent of syphilis starts systemic dissipation a few hours or days after inoculation. As early invasion of the central nervous system (CNS) may be seen in many patients infected with syphilis, however asymptomatic (5,6), neurological symptoms may be seen at any stage of the seen (6). In cases receiving penicillin treatment, which remains an effective method, neurosyphilis is usually expected at least 2 years after the start of the infection. However, due to the increase of the prevalence of HIV infections, patients with neurological involvement in earlier stages are reported (7). Many case series, especially 15-30% of early stage patients have been reported to have positive *T. pallidum* tests in the CSF (8,9). Fifty percent of neurologically symptomatic patients and 26% of

asymptomatic patients may have CSF involvement (9). Studies have shown that the spirochete is present in the lymph nodes minutes after and in the CNS hours after contamination (8).

Two of our cases presented with clinical complaints of the CNS, and both were found to have CNS involvement findings; on the other hand, we could not assess the CSF in the case who had presented with peripheral nervous system involvement and had long-term complaints, and this case was thought to have late-term syphilis symptoms. The other two patients were diagnosed during investigations to uncover the etiology.

Syphilis presents with an ulcer, or chancre sore resulting from the response occurring in the tissue eroded following sexual trauma within 9-90 days of encountering with the spirochete (5,10). This lesion is typically painless, soft and several in number (5). While local dissemination is towards lymph nodes, it is transported to other systems via hematologic route (5). Local immunity allows the ulcer to heal and spirochete accumulations to disperse systemically, causing the development of secondary syphilis. Usually 3-6 weeks after the development of a chancre sore, symptoms of secondary syphilis are seen, including palmar and plantar rash, generalized lymphadenopathy, orogenital mucosal lesions, and condyloma lata (5, 10). Rarely at this stage patchy alopecia, anterior uveitis, retinitis, cranial nerve involvement, meningitis, laryngitis, gastritis, hepatosplenomegaly, hepatitis, glomerulonephritis and periostitis may develop. This stage is followed by the latent stage, and 40% of the cases develop tertiary syphilis (5) at any time within 2 to 50 years after the onset of infection (11). Tertiary syphilis is characterized by gummatous lesions, cardiovascular and neurologic symptoms (5). Gummatous lesions may cause infiltrative or destructive lesions (11). The stage with cardiovascular and neurologic symptoms may also be defined as fourth stage syphilis. Late stage syphilis may cause stroke syndromes resulting from meningovascular involvement or parenchymal involvement as well as generalized paralysis or tabes dorsalis (5,11). It is clear that vasculitic processes play a role in the main pathophysiology in all stages (5). Although there was central nervous system involvement in our first two cases, their cerebral angiograms showed no signs suggesting vasculitis.

Neurological involvement, more specifically ocular involvement of the frontal and/or posterior segment may present as the only finding in almost all stages of the disease. Optic involvement may be seen as uni- or bilateral perineuritis of the eye, retrobulbar neuritis, optic neuritis, and papilledema (4). Two of our patients had optic involvement. The second case had a baseline CSF pressure of 28 mmH<sub>2</sub>O. Angiogram and venogram results excluded vascular events. When CSF pressure was measured after the patient was initiated on oral acetazolamide 250 mg tid, it was found to be 14 mm H<sub>2</sub>O and headache and blurred vision complaints were relieved. The presence of VEP pathology suggested accompanying optic nerve involvement. Syphilis has been shown to affect cranial nerves as well as very rarely cause cavernous sinus syndrome or inappropriate antidiuretic hormone (ADH) syndrome (12,13).

**Table 1.** EMG-ENG findings of Case 3

Nerve	Latency (msec)	Peak amplitude (µV)	Distance (cm)	Velocity (m/sec)
Sensory nerve conduction velocity				
Right Median-Digit II-Wrist	3.2	20.3	17	53.1
Right Sural-Wrist	6.8	9.0	22.5	33.1
Right Ulnar-Digit V-Wrist	2.55	16.1	14.5	56.9
Motor nerve conduction velocity				
Right Median-APB-Wrist	3.35	12.5	9	
Right Median-APB-Elbow	7.3	10.6	21	53.2
Right Ulnar-ADM-Wrist	2.4	14.9	8.3	
Right Ulnar-ADM-Below elbow	6.9	13.6	22	48.9
Left Comm peroneal-EDB-Wrist	4.9	1.3	11	
Left Comm peroneal-EDB-Fibular head	13.4	1.6	33	38.8
Right Tibial (Knee)-AH-Ankle	4.2	10.5	10	
Right Tibial (Knee)-AH-Fossa Poplitea	13.65	11.3	35.5	37.6
Left Tibial (Knee)-AH-Ankle	4.15	8.7	12	
Left Tibial (Knee)-AH-Elbow	14.25	4.9	34	33.7

Note: Right Common peroneal-tibial anterior nerve could not be evoked.  
 F Wave: H Reflex: Right common peroneal-EDB: 50.8 msec  
 Right Tibial (knee)-Gastrocnemius: 33.15 msec  
 Right Tibial (knee)-AH: 53.4 msec  
 Left Tibial (knee)-AH: 55.4 msec  
 Left common Peroneal-EDB: 51.8 msec

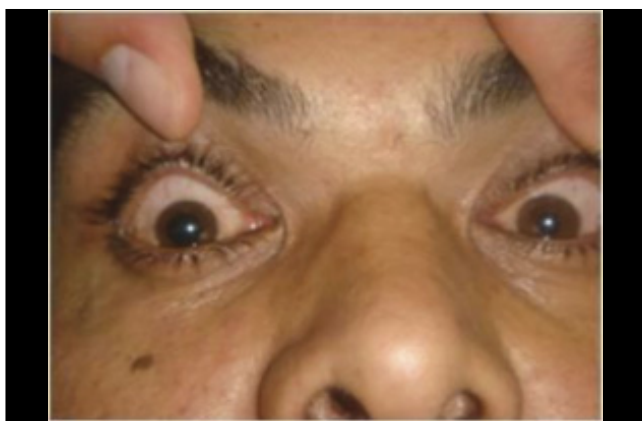The first case was found to have asymmetrical pupil width as well as tonic pupil response (Figures 1, 2). The electroneurographic evaluation found the nerve conduction velocities to be normal. As in the Cerny et al. case, there was bilateral tonic pupils and near-light reflex dissociation, and hypersensitive response to pilocarpine (Figures 1, 2) (14). Other potential local and systemic causes for bilateral tonic pupil were investigated and excluded. It was noted that our case was in combination with gummatous lesions, not with polyneuropathy as in Holmes-Adie syndrome (15).

Patients found to be serologically positive without any neurologic symptoms are defined as neurosyphilis (6). Our third case may be included in this group that requires large serial studies, with reservations. The patient was diagnosed with syphilis 12 years after the first complaints, did not receive adequate treatment and neurologic complaints had started 2 years after diagnosis. Following detailed examination, symptoms of peripheral nerve involvement were found causing atrophy and weakness in lower extremities (Figures 3).

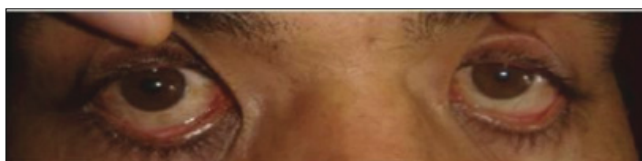
Diagnosis of early syphilis is based on showing *T. pallidum* in the lesion or the lymph node (7,10) via dark field microscope (DFM), direct fluorescent antibody dyeing method or dyeing the histologic tissue sample (5, 7, 10). The serology tests performed in early and late stages include treponemal enzyme immunoassay (EIA) designed to detect the treponema antigen, Venereal Disease Research Laboratory (VDRL) or rapid plasma reagin (RPR) tests based on the agglutination of *T. pallidum* particles (TPA) or hemagglutination (TPHA) and fluorescent antibody absorption (FTA-abs) or non-treponemal cardiolipin (5, 10). Polymerase

chain reaction test (PCR) allows detecting *T. pallidum* in various body fluids (9). TPHA is used as a screening test (7,10). Whereas all the treponemal tests are positive in latent syphilis, the VDRL test was positive in only 77% of the cases (5). Serology tests cannot distinguish between treponemal infections (5).

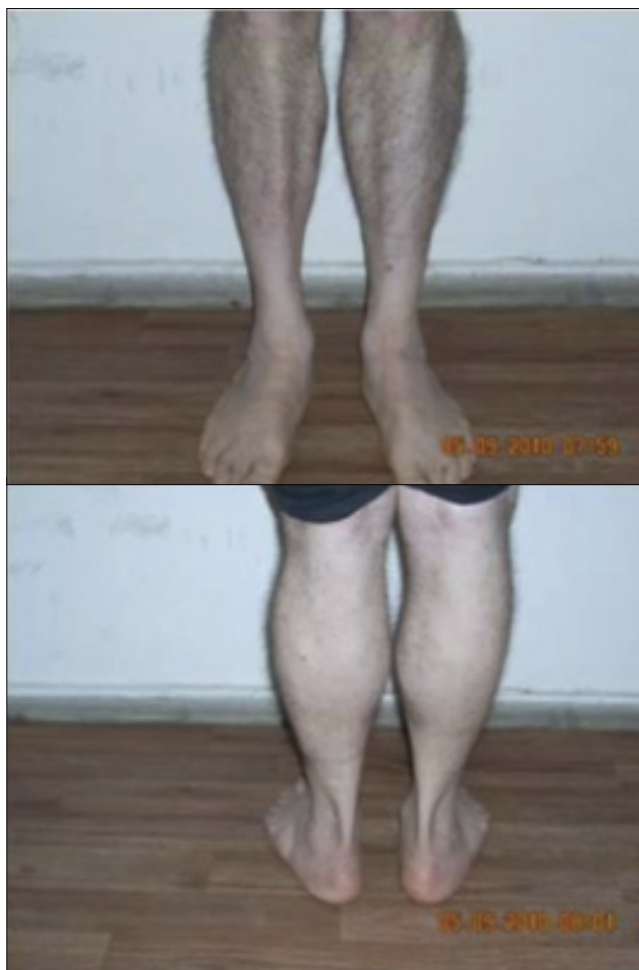Neurosyphilis is diagnosed based on a combination of clinical findings and reactive serology test results in the CSF (7, 16). Serum VDRL and TPHA tests and controls were positive in all our three cases. Whereas VDRL was negative and TPHA was positive in the first case, only both serology tests were found to be positive in the second case. Expert opinion considers VDRL positivity in CSF an important diagnostic criterion (16). Tests must be repeated for definitive diagnosis. Increase in number of cells or protein in CSF and/or reactive VDRL test positivity can be diagnostic in patients who are or are not clinically symptomatic (3). High level of protein alone is not significant for a diagnosis of neurosyphilis (5). Autoimmune conditions, HIV infections, pregnancy and intravenous drug use may cause false positive results (10). All patients with HIV infections are recommended to have CSF



**Figure 1.** Asymmetric pupil dilation pre-pilocarpine administration.



**Figure 2.** Hypersensitive response in both eyes following pilocarpine administration. Asymmetry continues in right eye.



**Figure 3.** Atrophy in peroneal muscles (in the front and rear muscle groups)

serology tests. All three of our patients were investigated for potential causes of immune deficiency and no significant results were found. If the CSF serology result is positive, there will be no response to classic penicillin treatment (16). However, a group of third stage patients may have symptoms suggesting tertiary syphilis without any symptoms or clinical signs (3). These cases should have CSF examination for effective treatment (3, 4).

All three patients were treated based on the syphilis treatment guidelines issued in 2008 (10). The guideline states that penicillin is the most potent antitreponemal antibiotic and parenteral penicillin use is deemed more suitable due to its higher bioavailability. Following a starting dose of benzathine penicillin 2.4 million units, once a day, procaine penicillin 600,000 U IM for 10-14 days is recommended. For patients who are allergic to penicillin, tetracycline – erythromycin 500 mg (4x1) or single doz azythromycin 2 gr is recommended (10). Our first case was administered tetracycline due to penicillin allergy; our second case received after vaginal smear was collected, as previously noted, a combination of miconazole and metronidazole, benzathine penicillin and acetazolamide, and our third case was diagnosed with tertiary syphilis and planned to receive benzathine penicillin on days 1, 8, 15 and then procaine penicillin on days 17-21 (10). It must be noted that tetracycline is a better option than others in patients allergic to penicillin, due to its passage into the CSF (10). Effectiveness of treatment is monitored via quantitative serology, especially VDRL and RPR tests (16).

These three cases showed us that syphilis is truly the “great imitator”, may involve all systems and mimic any disease of these systems. The early recognition and diagnosis, and timely treatment of treatable infections in the spectrum of neurologic diseases otherwise filled with difficult to treat chronic conditions that are sometimes impossible to treat, can be vitally important for the patient and the caregiver.

## References

1. Nicoll A, Hamers FF. Are trends in HIV, gonorrhoea, and syphilis worsening in western Europe? *Br Med J* 2002;324:1324-7.
2. From the Centers for Disease Control and Prevention. Primary and secondary syphilis United States, 2000-2001. *JAMA* 2002;288:2963-5.
3. Wöhrl S, Geusau A. Neurosyphilis is unlikely in patients with late latent syphilis and a negative blood VDRL-test. *Acta Derm Venereol* 2006;86:335-9.
4. Prokosch V, Thanos S. Emerging syphilitic optic neuropathy: critical review and recommendations. *Restor Neurol Neurosci* 2008;26:279-89.
5. Goh BT. Syphilis in adult. *Sex Transm Infect* 2005;81:448-52.
6. Ghanem KG. Neurosyphilis: A historical perspective and review. *CNS Neurosci Ther* 2010;16:e157-68.
7. Wicher K, Horowitz HW, Wicher V. Laboratory methods of diagnosis of syphilis for the beginning of the third millennium. *Microbes Infect* 1999;1:1035-49.
8. Collart P, Franceschini P, Durel P. Experimental rabbit syphilis. *Br J Vener Dis* 1971;47:389-400.
9. Lukehart SA, Hook EW 3rd, Baker-Zander SA, Collier AC, Critchlow CW, Handsfield. Invasion of the central nervous system by *Treponema pallidum*: implications for diagnosis and treatment. *Ann Intern Med* 1988;109:855-62.
10. French P, Gomberg M, Janier M, Schmidt B, van Voorst Vader P, Young H; IUST. IUSTI: 2008 European Guidelines on the Management of Syphilis. *Int J STD AIDS* 2009;20:300-9.
11. Viens NA, Watters TS, Vinson EN, Brigman BE. Case report: Neuropathic arthropathy of the hip as a sequela of undiagnosed tertiary syphilis. *Clin Orthop Relat Res* 2010;468:3126-31.
12. Noel CB, Moeketsi K, Kies B. Cavernous sinus syndrome, an atypical presentation of tertiary syphilis: case report and review of the literature. *Clin Neurol Neurosurg* 2011;113:65-7.
13. Milger K, Fleig V, Kohlenberg A, Discher T, Lohmeyer J. Neurosyphilis manifesting with unilateral visual loss and hyponatremia: a case report. *BMC Infect Dis* 2011;11:17.
14. Cerny R, Rozsypal H, Kozner P, Machala L. Bilateral Holmes-Adie syndrome as an early manifestation of the HIV neuropathy. *Neurol Sci* 2010;31:661-3.
15. Raji V, Dhanasegaran SE, Subramanian K, Sivaprakash S. Syphilitic myelodradiculopathy and pupillary light near disassociation: an overlap syndrome in a HIV positive individual. *Indian J Med Sci* 2006;60:421-2.
16. Farhi D, Dupin N. Origins of syphilis and management in the immunocompetent patient: facts and controversies. *Clin Dermatol*. 2010;28:533-8.