



Cerebral Hydatid Cyst: A Case Report

Serebral Kist Hidatik: Olgu Sunumu

Tuğçe Angın¹, Mehmet Çelebisoy¹, Ayşegül Noyan Karatepe¹, Mustafa Fazıl Gelal², Hatice Kübra Şirin¹

¹İzmir Katip Çelebi University Atatürk Training and Research Hospital, Clinic of Neurology, İzmir, Turkey

²İzmir Katip Çelebi University Atatürk Training and Research Hospital, Clinic of, Radiology, İzmir, Turkey

Summary

Hydatid cyst is a parasitic disease caused by larvae of Echinococcus. Central nervous system involvement is rare in patients with hydatid cyst. Cysts are asymptomatic until they reach large sizes. Clinical symptoms of central nervous system depends on the size and location of the lesion. The most common symptoms are headache and vomiting. Clinical diagnosis is confirmed by epidemiological evidence, medical history, clinical findings, serological tests and lesions determined with ultrasonography (US), computed tomography (CT) and magnetic resonance imaging (MRI). Surgery is the primary treatment modality. The purpose is to remove the cyst without rupture in surgical approach. In this article, a rare case of an adult with multiple intracranial lesions presenting with obvious clinical symptoms has been reported with imaging findings. (Turkish Journal of Neurology 2014; 20:87-90)

Key Words: Cerebral cyst, hydatid cyst, multiple cysts

Özet

Kist hidatik ekinokokkus larvalarınının sebep olduğu parazitik bir hastalıktır. Kist hidatik olgularında merkezi sinir sistemi tutulumu nadirdir. Kistler büyük boyutlara ulaşana kadar ciddi semptom vermezler. Klinik semptomlar, santral sinir sistemindeki lezyonun lokalizasyonuna ve boyutuna bağlıdır. Baş ağrısı ve kusma en sık görülen semptomlardır. Klinik tanı epidemiyolojik bulgular, öykü, klinik bulgular, ultrasonografi (US), bilgisayarlı tomografi (BT) ve manyetik rezonans görüntüleme (MRG) tespit edilen morfolojik lezyonlar ve serolojik testler ile konur. Temel tedavi yaklaşımı cerrahidir. Cerrahi yaklaşımda amaç kist rüptüre olmadan çıkarılmasıdır. Bu yazıda nadir görülen, multipl intrakraniyal yerleşimli, belirgin klinik veren erişkin bir olgu görüntüleme bulguları ile sunulmuştur. (Türk Nöroloji Dergisi 2014; 20:87-90)

Anahtar Kelimeler: Serebral kist, hidatik kist, multipl kist

Introduction

Hydatid syst is a parasitic disorder caused by the larvae of echinococcus. It is endemic in Mediterranean, South American, Middle Eastern countries and Australia (1-3). Isolated cranial placement is rare and it occurs when the larvae permeate the hepatic and pulmonary filters and infiltrate the brain through systemic circulation (4-6). The cysts can be single or multiple, unilocular or multilocular and with thin or thick membranes (3).

Cerebral hydatid cysts are often round, unilocular and solitary (5-8). Central nervous system involvement in hydatid cyst cases is rare and it constitutes only 1.6%-5.2% of all cases (4). In addition to the serological methods in the diagnosis of the hydatid cyst, imaging methods carry a lot of importance in the cases where there is cranial involvement. In this paper, we present a rare case of multiple intracranially located cysts that manifests distinct clinical properties and their imaging findings.

Address for Correspondence/Yazışma Adresi: Tuğçe Angın MD, İzmir Katip Çelebi University Atatürk Training and Research Hospital, Clinic of Neurology, İzmir, Turkey Gsm: +90 535 461 42 00 E-mail: tugceangin@gmail.com

Received/Geliş Tarihi: 10.06.2013 **Accepted/Kabul Tarihi:** 30.09.2013

Case

The thirty four year old female patient came to our hospital with headache complaints. In her medical history, she stated that she had an operation to remove a hydatid aortic cyst at an outside surgery center and had been having headaches since then. The headache's intensity has increased and she started having balance problems during walking. When asked for more details, she said she keeps her dog in her yard where she also grows her produce. Her neurological examination showed left hemiparesis. Her routine laboratory tests were normal. Her cranial magnetic resonance imaging (MRI) showed 6 cysts in her right frontotemporoparietal and right frontoparietal regions, some of which were multilocular intraaxial. The masses in the right hemisphere measured approximately 35x33 mm, 23x22 mm, 25x25 mm and 17x14 mm, and the ones on the left were measured as 16x15 mm and 17x15mm. It was seen that the right lateral ventricle was constricted and median line structures were displaced to the left by 7 mm, possibly due to mass effect. The walls of the two cystic lesions, one in each side, appeared to have thickened and with high contrast and surrounded by edema (Figure 1A, 1B). The lesions appeared to be congruent with the hydatid cysts type with the lesions with contrast-holding walls and surround-edema being infected. Hemagglutination test for the hydatid cyst was negative. In her transthoracic echocardiography, and lung and abdominal tomography, there were no signs of hydatid cysts. She was then diagnosed with cerebral hydatid cyst and started on 10 mg/kg/day Albendazole. Hydatid cysts were removed in 2 sessions without being ruptured using Dowling method. The surgical areas were cleaned with sodium chloride. The histopathological examination of the removed material was congruent with hydatid

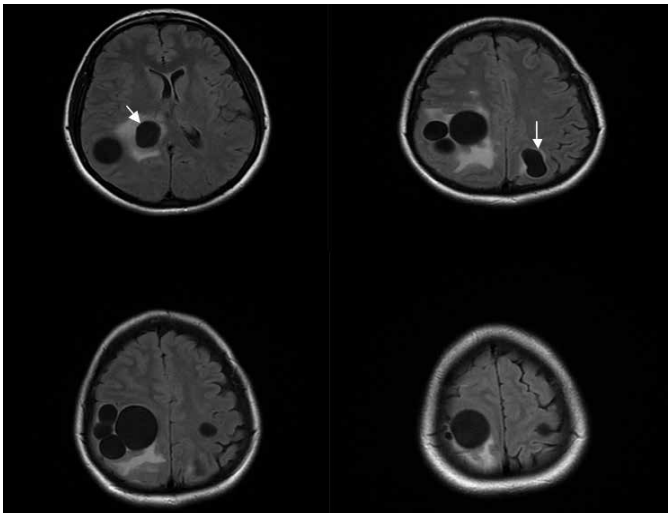


Figure 1A. Multiple intraaxial cystic masses, some of which are multilocular, are seen in both hemispheres in the axial FLAIR and T2 images. One cyst in each side on the parietal lobes have thickened walls and surrounding edema whereas others do not have edema (the ones that do have edema are marked with arrows).

cyst. Albendazole treatment was continued in the post-operative stage. In the control MRI, there were liquid accumulations on the lodges of both parietal operations and a 5 mm radius peripheral, contrast-holding lesion in the superior and posterior parts of right frontal lobe. This lesion existed also in the pre-operative MRI but it increased moderately in size. The infected residue was interpreted as hydatid cyst and monitored (Figure 2A, 2B). The patient who had tonic clonic seizures in the follow-ups was started on 1000 mg/day levetiracetam. At the three-month follow-up visit, the patient did not have any neurological deficits besides left hemiparesis.

Discussion

Hydatid cyst is a parasitic disease caused by the larvae of echinococcus. In humans, the disease was commonly caused by echinococcus granulosus and less frequently by echinococcus multilocularis. Cystic echinococci are composed of a laminar layer on the inside (endocyst) and a germinal layer on the outside (ectocyst). The fibrous capsule of the cyst (pericyst) is formed by

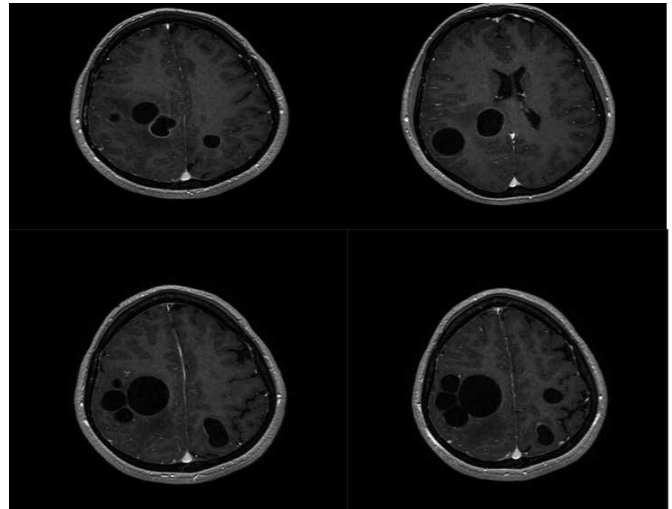


Figure 1B. Contrasting was seen in the cystic walls with edema in the postcontrast axial slices.

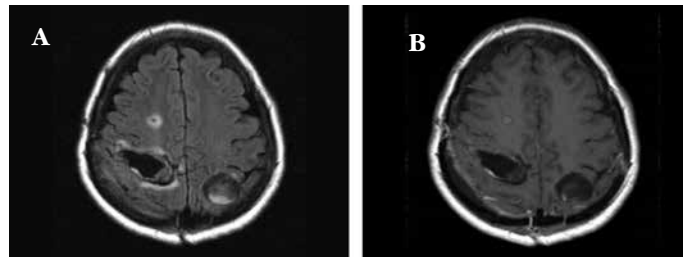


Figure 2A-2B. Postoperatif dönemde. FLAIR T2 ve B. Postkontrast T1 ağırlıklı aksiyal kesitlerde kistlerin operasyon ile boşaltıldığı ve operasyon lojunda sıvı birikimi olduğu görülmektedir. Sağ frontalde ise 5 mm çaplı periferik kontrast tutan lezyon izlenmiş olup bu lezyon preoperatif MRG'deki boyutlarına göre hafifçe büyüyen rezidü enfekte hidatik kisti temsil etmektedir.

the host organism. This fibrous capsule is fed by blood vessels. Germinal layer and capsule are formed by daughter venule endoproliferation (internal budding) (3). Humans are coincidental intermediate hosts (4,7,9). Humans are infected by contact with animals or consuming foods contaminated with parasite eggs (1,4). Orally ingested eggs are hatched in the gastrointestinal tract and the embryos propagate to the rest of the body. The embryo medutes into the cystic larvae (hydatid cyst) (10). Our case indicated owning a dog as a pet. The most frequent occurrences are in the liver (60-75%) and secondarily in the lungs (15-30%) (9). Seventy five percent of hydatid cysts are seen in children (4,11). The reason for this high prevalence in kids is argued to be the patent ductus arteriosus being still open (1).

Cerebral hydatid cyst is histologically categorized into two: primary and secondary. Primary hydatid cyst is more commonly seen. The primary cyst tends to lodge along the cerebral artery supply area, especially on the parietal lobe (3,5,12,13). It is seen after the larvae escapes through the lymphohemorrhagic, pulmonary, hepatic and cardiac filters and reaches the brain, and it is often singular (7,9,14). The secondary form is often seen when the primary extracranial cyst is ruptured surgically, spontaneously or due to trauma, and it is often seen in multiples (2,7,8,9,14). The fact that our case had an extracranial hydatid cyst operation performed in the past and that there were multiple cerebral cysts, it made us think of the secondary form due to the surgical rupture of the aortic cyst.

Cysts do not produce any symptoms until they grow into a large size. The clinical symptoms depend on the location of the cyst on the central nervous system and its location (4). Headaches and vomiting are the most common ones (3,11). The symptoms develop slowly and the neurological deficits, caused by the increased intracranial pressure, are seen towards the late stage (4,9). Papillary edema is commonly seen in children while in adults, focal findings such as hemiparesis, speech disorders, hemianopia and epileptic seizures can be seen depending on the location of the cyst (1). In our case, headache was the starting symptom which was later followed by hemiparesis.

Clinical diagnosis is made under the light of epidemiological findings, medical history, clinical findings, lesions detected with ultrasound (US), computerized tomography (CT) and MRI, and serological tests. While serological tests had been included in the diagnostic workup for the hydatid cysts, its importance has been reduced by the advancements in imaging techniques (8). In CT, the cysts appear round, smooth and thin-walled lesions giving values similar to cerebrospinal fluid (CSF) and it was reported that they do not show surrounding edema unless they get infected (2,4,5,6). Magnetic resonance imaging is superior in displaying the cyst's wall and surrounding edema compared to CT (1,4). In MRI, cystic fluid has the same intensity as CSF in T1 and T2-weighted sequences and its wall appear as a low signal intensity rim in both sequences. T2-weighted images are better than T1-weighted ones in revealing the cyst's walls (5). In the case of inflammatory reaction, contrasting around the cyst and surrounding edema might be seen

(9). Due to having good protection and efficient vascularization, cerebral hydatid cysts rarely degenerate and therefore calcification is seen in less than 1% of them (15).

The differential diagnostic for cerebral hydatid cysts should include arachnoid and porencephalic cysts, cystic tumors and cerebral abscess (1,3,9,13). Arachnoid cysts are not round and they are not covered by the brain tissue. Porencephalic cysts are related to ventricles. Cystic tumors often have soft-tissue components showing distinct contrast. Cerebral abscess show distinct peripheral edema and annular contrasts (1,9,13).

The basic treatment method is surgery (8). The aim in the surgical intervention is to remove the cyst without rupturing it (4,5,8). Any possible rupture may cause inflammatory reaction and recurrence (5). The most curative surgical method is to remove the cyst using Dowling's technique and washing the area with hypertonic sodium chloride (2,4). Cleaning the area with sodium chloride decreases the chance of recurrence (1,9). In our case, the cysts were removed in 2 sessions using Dowling's technique. When they cysts are infected, hydatid cysts are so fused into the brain tissue that removal without rupturing the cyst is impossible (2). Darwasah et al. reported that surgical methods to remove multiple and infective brain cysts fail in patients with cardiac cystic lesions (7). There is need to shrink the cyst in the preoperative stage, and drug treatment to prevent recurrence in the postoperative stage (1,7). In elderly patients, drug treatment alone may be used for small calcific cysts (7). Albendazole and mebendazole are used in the medical treatment (5). It is known that these drugs pass blood brain barrier and infiltrate hydatid cyst membrane (2). The penetration of the drug changes depending on the thickness of the membrane and the presence of calcification. Thin membrane and lack of calcification may produce favorable response to treatment (2). Albendazole is used 10-15 mg/kg/day, blocking glucose use and acting as a parasiticide (5).

Subdural effusion and obstructive hydrocephalus are well-known postoperative complications of the cyst (1). Epilepsy rates in the postoperative intracranial hydatid cyst during the 2-year follow-up in Arana-Iniguez patient series was reported as 7% (16). Our case also had seizures and was started on antiepileptic treatment. Focal findings and non-bacterial meningitis are well-known conditions after the surgery. The anaphylactic reaction due to the rupturing of the cyst during the surgery is the leading cause of mortality. Recurrence and multiple hydatid cyst are bad prognostic factors (1).

Our patient's case is important in the sense that multiple cranial cysts of this kind in adults are rare in the literature. The fact that her history included a prior hydatid cyst operation suggested that the later occurrence was the secondary form due to the rupturing of the first cyst during the operation. Good prognosis during the three-month follow-up stage motivated the presentation of this case in the light of past literature on the topic.

References

1. Ciurea AV, Fountas KN, Coman TC, Machinis TG, Kapsalaki EZ, Fezoulidis NI, Robinson JS. Long-term surgical outcome in patients with intracranial hydatid cyst. *Acta neurochirurgica* 2006;48:421-426.

2. Yüceer N, Güven MB, Yılmaz H. Multipl hydatid cysts of the brain: A case report and review of literature. *Neurosurg* 1998;21:181-184.
3. Bükte Y, Kemalöđlu S, Nazarođlu H, Özkan Ü, Ceviz A, Şimsek M. Cerebral hydatid disease: CT and MR imaging findings. *Swiss Med Wkly* 2004;134:459-467.
4. Özkan Ü, Kemalöđlu M, Selçuki M. Gigantic intracranial mass of hydatid cyst. *Child's Nervous System* 2001;17:623-625.
5. Kalaitzoglou I, Drevelengas A, Petridis A, Palladas P. Albendazole treatment of cerebral hydatid disease: evaluation of results with CT and MRI. *Neuroradiology* 1998;40:36-39.
6. Karadađ Ö, Gürelık M, Özüm Ü, Göksel HM. Primary multiple cerebral hydatid cysts with unusual features. *Acta Neurochirurgica* 2004;146:73-77.
7. Darwazah AK, Zaghari M, Eida M, Batrawy M. Left ventricular endocardial echinococcosis associated with multiple intracranial hydatid cysts. *Journal of Cardiothoracic Surgery* 2013;8:104.
8. Tuncer C, Ahmet Ö, Aydın Y. Multiple intracranial hydatid cysts in a boy. *Turkish neurosurgery* 2009;19:203-207.
9. M. Turgut. Intracranial hydatidosis in Turkey: its clinical presentation, diagnostic studies surgical management, and outcome. A review of 276 cases. *Neurosurg Rev* 2001;24:200-208.
10. Grossman RI, Yousem DM. *Infectious and Noninfectious Inflammatory Diseases of the Brain: Neuroradiology the requisites*, 2th ed. Philadelphia Elsevier Mosby: 2003:319-320.
11. Erşahin Y, Mutluer S, Güzelbađ E. Intracranial hydatid cyst in children. *Neurosurgery* 1993;33:219-224.
12. Evliyaođlu C, Yüksel M, Gül B, Kaptanođlu E, Yaman M. Growth rate of multiple intracranial hydatid cysts assessed by CT from the time of embolisation. *Neuroradiology* 1998; 40; 387-389.
13. Beşkonaklı, E, Solarođlu I, Tun K, Albayrak L. Primary intracranial hydatid cyst in the interpeduncular cistern. *Acta Neurochirurgica* 2005;147:781-783.
14. Kemalöđlu S, Özkan Ü, Bükte Y, Acar M, Ceviz A. Growth rate of cerebral hydatid cyst, with a review of the literature. *Child's Nervous System* 2001;17:743-745.
15. Taş F, Gümüş C, Atalar M, Taş A, Eđilmez H, Bulut S. Serebral Kist Hidatiklerin Bilgisayarlı Tomografi Bulguları 2002;24:113-118.
16. Arana-Iniquez R. *Echinococcus Handbook of clinical neurology Infections of the Nervous System*. North Holland Publishing Company Amsterdam-New York, Oxford 1978;35:175-207.