



# Seizure and Ischemic Attack Following Bee Sting

## Arı Sokması Sonrası Nöbet ve İskemik İnme

Aynur Yurtseven<sup>1</sup>, Yahya Güvenç<sup>2</sup>

<sup>1</sup>Dr. Nafiz Körez Sincan State Hospital, Clinic of Emergency Medicine, Ankara, Turkey

<sup>2</sup>Dr. Nafiz Körez Sincan State Hospital, Clinic of Neurosurgery, Ankara, Turkey

### Summary

Bee stings are the most frequently encountered among insect-related emergencies. Often bee stings present only with local allergic reactions; occasionally severe clinical conditions may also be encountered, including polyneuritis, parkinsonism, encephalitis, acute disseminated encephalomyelitis, Guillain-Barre syndrome, myocardial infarction, pulmonary edema, hemorrhage, hemolytic anemia, and renal disease. A rare case of bee sting with seizure is presented herein.

**Keywords:** Bee sting, neurological signs, seizure, ischemic attack

### Öz

Böcek sokmaları içinde en sık karşılaştığımız arı sokmalarıdır. Genellikle arı sokmasından sonra sıklıkla görülen sadece lokal allerjik reaksiyonlardır. Bazen de çok ciddi klinik tablolarla da karşımıza çıkabilir. Nadir görülen bu klinik bulgular arasında polinöropati, parkinsonizm, ensefalit, akut dissemine ensefalomyelit, Guillain-Barré sendromu, miyokard enfarktüsü, pulmoner ödem, kanamalar, hemolitik anemi ve böbrek yetmezliği vardır. Burada oldukça nadir görülen arı sokması sonrası konvülsiyon geçiren bir olgu sunulmaktadır.

**Anahtar kelimeler:** Arı sokması, nörolojik bulgular, konvülsiyon, iskemik inme

### Introduction

Venomous animals pose a significant health risk in most places of the world, particularly in Africa, Southeast Asia, and Tropical America, where epidemiologic studies on these animals are limited to snake bites and scorpion stings. Little information is known about the remaining venomous animals (1). Although severe reactions may be seen following bee stings and other insect bites, we do not have sufficient information about their effects. These reactions may be local or systemic. Local reactions are often characterized by pain, swelling, erythema, itching, and blister, and overall, type 1 mast cells surround the sting site and mediate an anaphylactic reaction (2).

Toxication due to honey bee or wasp varies in their clinical manifestations. Most people often present with local allergic reactions including pain, redness, and swelling at the site of

sting, which generally fades in a couple of hours. However, signs in severe cases may include myocardial infarction, pulmonary edema, bleeding, kidney failure, and life threatening anaphylactic shock (3). Neurologic symptoms have scarcely been reported in the literature but include encephalitis, acute disseminated encephalomyelitis, extrapyramidal clinical signs, and polyneuritis (2,4). In this case report, we present a patient who presented with seizure after being stung by a bee.

### Case Report

A woman aged 70 years old presented to the emergency clinic of our hospital in the post-ictal period of a seizure. The patient's relatives reported that she had a generalized tonic-clonic seizure that lasted 2-3 minutes following a bee sting. In the physical examination, her overall condition was moderate, consciousness

**Address for Correspondence/Yazışma Adresi:** Aynur Yurtseven MD, Dr. Nafiz Körez Sincan State Hospital, Clinic of Emergency Medicine, Ankara, Turkey  
Phone: +90 505 563 01 73 E-mail: aynur\_ogut@mynet.com

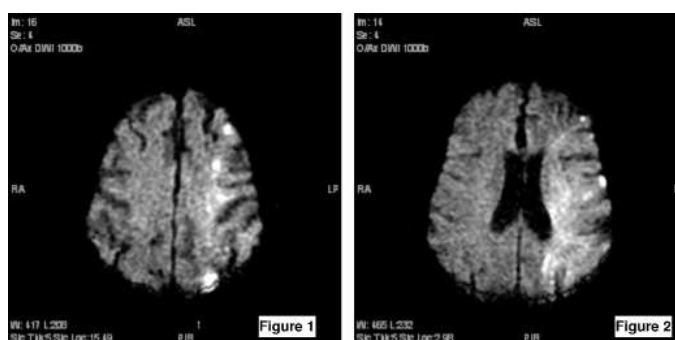
**Received/Geliş Tarihi:** 24.07.2014 **Accepted/Kabul Tarihi:** 29.10.2014

was confused, and the patient responded verbally to painful stimuli with a Glasgow Coma Score (GCS) of 11 at arrival. There was no sign of meningeal irritation. A hyperemic lesion was noted due to bee sting on her right arm. The patient's medical history revealed that she had an atopic tendency, and no known epileptic diseases. She also had coronary artery disease, diabetes mellitus, and hypertension, and regularly took her medication.

Laboratory examinations showed that her hemoglobin count was 10.1 gm/dL, leukocyte count was 11 070 cells/mm<sup>3</sup>, and levels of glucose and electrolyte were normal. Brain tomography was normal. Airway support was provided and pheniramine maleate, an H1 receptor antagonist, was administered at 1 mg/kg, and methyl prednisolone was administered i.v. at 1 mg/kg in 100 cc physiologic serum. A loading dose of phenytoin sodium was administered upon the observation of another generalized tonic-clonic seizure in the emergency ward. An emergency magnetic resonance imaging (MRI) was planned but could not be obtained on the first day due to a technical problem with the scanner. The patient was referred to the neurology clinic and admitted. Her consciousness returned gradually and seizures did not repeat, but the patient abruptly lost consciousness on day 3, had no verbal response, and left flexor response was obtained to painful stimuli. Tendon reflexes were bilaterally absent. Cranial MRI delineated multifocal diffusion restriction in line with acute ischemia at the gray-white matter junction in the left frontoparietal area. Figures 1 and 2 demonstrate the cranial imaging findings. The patient was intubated and admitted to the intensive care unit upon observation of superficial respiration. During her stay in the intensive care unit, respiratory and cardiac arrest occurred and the patient died. With this case, we wanted to remind physicians that seizures can be seen due to bee sting, albeit rarely, and may be followed by a cerebrovascular event.

## Discussion

Allergic reaction to bee sting might include signs of skin reaction (erythema, itchiness, urticaria, and angioedema), respiratory system effects (larynx edema and bronchospasm), and cardiovascular (myocardial depression, hypotension, and shock) and gastrointestinal system events (nausea, vomiting, fecal incontinence) (5,6,7). As a result, severe anaphylactic shock can lead to cerebral or myocardial ischemia accompanied



**Figure 1, 2.** Multifocal diffusion restriction at the gray-white matter junction in left frontoparietal region in line with acute ischemia in cranial magnetic resonance imaging

by permanent sequelae (7). The clinical picture of bee sting may occasionally include diffuse alveolar hemorrhage, rhabdomyolysis, thrombocytopenic purpura, and vasculitis (5,6,7,8). Our case was deemed noteworthy for presenting with epileptic seizure following bee sting despite having no history of epilepsy or cerebrovascular event. This is a rare clinical presentation of bee sting according to the literature.

Bee venom contains several chemical components that contribute to the clinical picture, including enzymes (phospholipases, hyaluronidase) and biologic amines (histamine, serotonin, dopamine, norepinephrine, and acetylcholine) (9). Our patient presented in the post-ictal period of seizure, and seizures continued during the emergency clinic and ward admissions.

Seizures due to bee sting are often associated with the dose of venom, and have been defined as behavioral seizures. Studies performed on mice injected with phospholipase A2, including bee venom, have suggest that these substances bind to the related receptors on specific neuronal sites and lead to seizure. These seizures have been reported to be refractory to the blockage of calcium and potassium channels or NMDA and GABA receptors (10).

Neurologic signs that involve both peripheral and central nervous system include Guillain-Barre syndrome, multiple sclerosis, optic neuritis, Parkinsonism, and transvers myelitis. Potential mechanisms responsible for the neurologic involvement stem from immunological injury similar to the Guillain-Barre syndrome or several forms of encephalomyelitis, or direct reaction between bee venom and apamin receptors (11). In light of this information, the results of our case were interpreted as non-immunologic toxic signs.

Providing life support should be the priority in cases of anaphylaxis. Recommendations including supply of oxygen, administering adrenalin (0.5 mg intramuscularly in an adult of 1/1000 may be repeated at 10-15 minute intervals, 0.01 mL/kg intramuscularly in children), diphenhydramine, prednisolone, ranitidine, fluids or positive inotropes if necessary, and beta-2 agonists and aminophylline in the presence of bronchospasm (12). Airway support was provided to our patient in the emergency ward, and anti-allergic and prophylactic anti-anaphylactic therapies were administered in line with the recommended treatment protocols. Generalized tonic-clonic seizures could be controlled with the onset of anti-epileptic therapy.

According to the criteria released by the World Health Organization, stroke has been defined as "rapidly developing clinical symptoms and/or signs of focal or global disturbance of cerebral function, lasting more than 24 hours or leading to death, with no apparent cause other than that of vascular origin (13)." Cerebrovascular diseases are one of the most common causes of seizure in adults and the elderly, with an etiologic role in 30-45% of all seizures that occur in patients aged over 60 years (14). Studies have reported a wide range for the rate of post-stroke epileptic seizures, i.e. 0.4-42.8% (14,15,16). The etiologic investigations in our patient demonstrated that vital signs, blood examinations, and brain CT were normal at first presentation. MR imaging could not be performed due to a technical problem with the scanner, which leads us to believe that the seizure may have been post-stroke; however, the patient had no risk factors to explain the seizure other than the bee sting. Further studies should be performed to

elucidate whether the seizure resulted directly from the toxic effect of bee venom, or stroke due to respiratory distress caused by the toxic substance. However, overall it should be noted that seizure etiology may include a rarely reported condition of bee sting, as well as the well-known cerebrovascular events. The case presented herein, highlights the fact that although rarely, seizures may result from bee sting and emergency wards should be prepared for such cases.

**Concept:** Aynur Yurtseven, Yahya Güvenç, **Design:** Aynur Yurtseven, Yahya Güvenç, **Data Collection and Processing:** Aynur Yurtseven, Yahya Güvenç, **Analysis or Interpretation:** Aynur Yurtseven, Yahya Güvenç, **Literature Search:** Aynur Yurtseven, Yahya Güvenç, **Writer:** Aynur Yurtseven, Yahya Güvenç, **Peer-review:** External and internal peer-reviewed. **Conflict of Interest:** Authors have no conflicts of interest to declare. **Financial Support:** Our study has not received financial support from any institution or person.

## References

- Cardoso DC, Cristiano MP, Raymundo MS, Costa S, Zocche JJ. Epidemiology and injuries (1994-2005) resulting from poisonous animals in southern Santa Catarina State, Brazil. *J Public Health* 2007;15:467-472.
- Atili Suresh Venkata Satya, Gambhir IS, Suba Rao S, Kumar M, Mehata H, Gogia A, Raju SHK. A case of post bee sting encephalitis. *AJNS* 2006;25:69-72.
- Sachdev A, Mahapatra M, D'Cruz S, Kumar A, Singh R, Lehl SS. Wasp sting induced neurological manifestations. *Neurol India* 2002;50:319-321.
- Agarwal V, DCruz S, Sachdev A, Singh R, Kapoor V. Quadriplegia following wasp sting: an unusual reaction. *Indian J Med Sci* 2005; 59:117-119.
- Lam SM. Acute pulmonary hemorrhage following a honeybee sting: a case report. *J Microbiol Immunol Infect* 1998;31:133-136.
- Bilo MB, Bonifazi F. The natural history and epidemiology of insect venom allergy: clinical implications. *Clin Exp Allergy* 2009;39:1467-1476.
- Müller UR. [Insect venom allergy]. *Ther Umsch* 1994;51:38-44.
- Reisman RE. Unusual reactions to insect stings. *Curr Opin Allergy Clin Immunol* 2005;5:355-358.
- Golden DB, Valentine MD, Kagey-Sobotka A, Lichtenstein LM. Regimens of hymenoptera venom immunotherapy. *Ann Intern Med* 1980;92:620-624.
- Gandolfo G, Lambeau G, Lazdunski M, Gottesmann C. Effects on behaviour and EEG of single chain phospholipases A2 from snake and bee venoms injected into rat brain: search for a functional antagonism. *Pharmacol Toxicol* 1996;78:341-347.
- Golden DB, Valentine MD, Kagey-Sobotka A. Regimens of hymenoptera venom immunotherapy. *Ann Intern Med* 1980;5:620-624.
- Hatano S. Experience from a multicenter stroke register: a preliminary report. *Bull World Health Organ* 1980;58:113-130.
- Velioglu S. İnme ve epilepsi. Editörler: Bora I, Yeni N, Gürses C. *Epilepsi*. İstanbul: Nobel Tıp Kitabevleri, 2008;365-367.
- Bladin CF, Alexandrov AV, Bellavance A, Bornstein N, Chambers B, Coté R, Lebrun L, Pirisi A, Norris JW. Seizures after stroke: a prospective multicenter study. *Arch Neurol* 2000;57:1617-1622.
- Dhanuka AK, Misra UK, Kalita J. Seizures after stroke: a prospective clinical study. *Neurol India* 2001;49:33-36.
- Kalpakioglu AF. Insect Allergy. *Allergy Asthma Immunology* 2003;1:44-53.