



Bilateral Peroneal Neuropathy after Obesity Surgery

Obezite Cerrahisi Sonrası Bilateral Peroneal Nöropati

Ramazan Şencan, Uygur Utku, Mustafa Gökçe
Sütçü İmam University, Department of Neurology, Kahramanmaraş, Turkey

Summary

A woman aged 33 years presented with progressive bilateral foot drop, which had begun three months ago previously. Her medical history revealed that she had undergone bariatric surgery seven months ago and had lost 65 kgs in six months (from 147 kgs to 82 kgs). Bilateral peroneal neuropathy was determined at the fibular head on her electromyography study. The case highlights the importance of an awareness of peroneal neuropathy after massive weight loss. Diet modification and physical therapy should be considered for these patients.

Keywords: Obesity surgery, weight loss, peroneal neuropathy

Öz

Otuz üç yaşında kadın hasta üç ay önce başlayan ve artan düşük ayak şikayeti ile başvurdu. Yedi ay önce obezite cerrahisi geçirmişti ve yaklaşık altı ay içerisinde 65 kilo vermişti (147-82 kg). Elektromiyografi çalışmasında fibula başı düzeyinde bilateral peroneal nöropati saptandı. Olgu aşırı kilo kaybı sonrası peroneal nöropati gelişebileceğine dikkat çekmektedir. Bu hastalara uygun diyet ve egzersiz desteği verilmesi akılda bulundurulmalıdır.

Anahtar kelimeler: Obezite cerrahisi, kilo kaybı, peroneal nöropati

Introduction

Peroneal neuropathy results in clinical symptoms of weakness of the ankle dorsiflexor and evertor muscles (1). Peroneal palsy commonly occurs due to compression or traction of the peroneal nerve around the fibular head and foot drop is the most common presentation of peroneal neuropathies (2). It may also be seen in a wide variety of other clinical conditions. Trauma, malignancies, infections, and defects of anatomical structures are the main etiologic causes of peroneal neuropathy (3). Weight loss is also accepted as a risk factor for peroneal neuropathies (2,4). Here, we present bilateral peroneal neuropathy as a complication of massive weight loss after obesity surgery.

Case Report

A woman aged 33 years presented to our clinic with progressive bilateral foot drop. She reported weakness in her lower extremities with loss of dorsiflexion in her ankles for the last three months. Seven months ago, she had undergone bariatric surgery (laparoscopic sleeve gastrectomy), which had physically restricted the size of her stomach. By the end of the 6th month, the patient had lost 65 kgs (from 147 kg to 82 kg). She had no concomitant disease. Her blood count, serum biochemistry, thyroid function, and vitamin B12 levels were normal. There was weakness of feet dorsiflexion/eversion in her neurologic examination (2/5).

Nerve conduction studies were used to localize the nerve injury. Measurements were taken from the patient's extensor digitorum

Address for Correspondence/Yazışma Adresi: Uygur Utku MD, Sütçü İmam University, Department of Neurology, Kahramanmaraş, Turkey
Phone: +90 505 572 59 32 E-mail: utkuzar@gmail.com

Received/Geliş Tarihi: 28.03.2014 **Accepted/Kabul Tarihi:** 16.01.2015

brevis muscles while being stimulated from above and below fibular heads. There was a 70% block in compound muscle action potential amplitudes on her electrophysiologic study (Figure 1). There was also a significant drop in motor conduction velocities across the fibular heads. The left peroneal nerve was affected more than the right. In the needle electromyography of bilateral tibialis anterior and peroneus longus muscles, there were increased insertional activity, fibrillations, sharp waves, and reduced recruitments, and also motor unit potentials of normal amplitude, duration, and phasicity. Conduction studies of the bilateral sural-, posterior tibial-, ulnar and median nerves were within the normal range. Needle electromyography of bilateral gastrocnemius-, short head of biceps, femoris-, and gluteus medius muscles were normal. Denervation potentials were not observed when the lumbar paraspinal muscles were examined. After these procedures, all other causes of foot drop were excluded and isolated partial lesion of bilateral peroneal nerves on the fibular head was diagnosed. The patient was also examined by a physician from orthopedics and her lumbar spinal magnetic resonance imaging was within normal ranges. Diet modification was implemented after the etiologic investigation.

Discussion

Peroneal neuropathy has rarely been observed in starvation, anorexia, and other situations of massive weight loss (5,6). The mechanism in peroneal neuropathy after massive weight loss is probably related with the peroneal nerve, which is quite superficial at the fibular neck and fat tissue around the nerve protects the common peroneal nerve against compression. Our patient reported bilateral foot drop after she had lost approximately 65 kg.

Local trauma and compression are the most common causes of nerve entrapment. In addition, defects of anatomic structures may create angulations, compression, and stretching of the nerve. In this case, bilateral peroneal neuropathy could be accepted as a complication of massive weight loss after bariatric surgery because our patient had no anatomic defects or history of trauma, prolonged kneeling or squatting. Laparoscopic sleeve gastrectomy

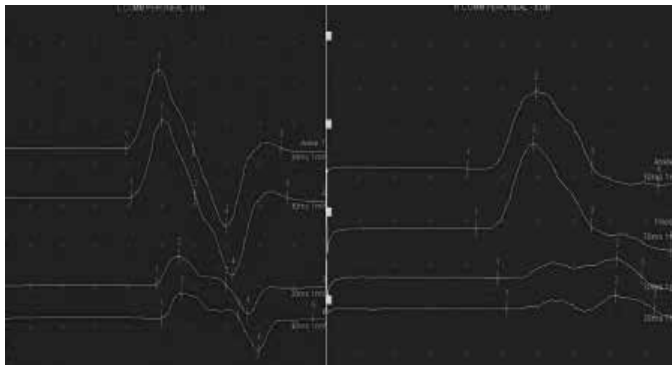


Figure 1. Low amplitude, or drop in amplitude across fibular head. Slowed conduction velocity across fibular head

is a bariatric surgery technique in which the stomach is divided vertically to reduce it to about 25% of its original size, and is increasingly being used as a stand-alone procedure. The pyloric valve at the bottom of the stomach is left intact, which means that stomach function and digestion are unaltered (7).

The prognosis for peroneal neuropathy after weight loss is good if any underlying polyneuropathy is not severe (6). Diet modification, physical therapy and rehabilitation programs should be the first-line treatment options. Nutritional replacement, metabolic support, and dietary programs are important in treatment. Surgical therapy might be the second option in disabling cases, especially in patients with bilateral involvement (8). Our patient was referred to our hospital dietician.

Conclusion

It is important to keep peroneal neuropathy in mind as a complication of massive weight loss after bariatric surgery; diet modification in addition to physical therapy might be the first-choice treatment.

Informed Consent: Consent form was filled out by all participants. **Concept:** Ramazan Şencan, Uygur Utku, Mustafa Gökçe, **Design:** Ramazan Şencan, Uygur Utku, Mustafa Gökçe, **Data Collection or Processing:** Ramazan Şencan, Uygur Utku, Mustafa Gökçe, **Analysis or Interpretation:** Ramazan Şencan, Uygur Utku, Mustafa Gökçe, **Literature Search:** Ramazan Şencan, Uygur Utku, Mustafa Gökçe, **Writing:** Ramazan Şencan, Uygur Utku, Mustafa Gökçe, **Peer-review:** Externally peer-reviewed, **Conflict of Interest:** No conflict of interest was declared by the authors, **Financial Disclosure:** The authors declared that this study has received no financial support.

References

- Marciniak C. Fibular (peroneal) neuropathy: electrodiagnostic features and clinical correlates. *Phys Med Rehabil Clin N Am* 2013;24:121-137.
- Aprile I, Caliandro P, La Torre G, Tonali P, Foschini M, Mondelli M, Bertolini C, Piazzini DB, Padua L. Multicenter study of peroneal mononeuropathy: clinical, neurophysiologic, and quality of life assessment. *J Peripher Nerv Syst* 2005;10:259-268.
- Grantz M, Huan MC. Unusual peripheral neuropathies. Part 1: extrinsic causes. *Semin Neurol* 2010;30:387-395.
- Sherman DG, Easton JD. Dieting and peroneal nerve palsy. *JAMA* 1977;238:230-231.
- MacKenzie JR, LaBan MM, Sackeyfio AH. The prevalence of peripheral neuropathy in patients with anorexia nervosa. *Arch Phys Med Rehabil* 1989;70:827-830.
- Elias WJ, Pouratian N, Oskouian RJ, Schirmer B, Burns T. Peroneal neuropathy following successful bariatric surgery. Case report and review of the literature. *J Neurosurg* 2006;105:631-635.
- Colquitt JL, Pickett K, Loveman E, Frampton GK. Surgery for weight loss in adults. *Cochrane Database Syst Rev* 2014;8:CD003641.
- Aprile I, Caliandro P, La Torre G, Tonali P, Foschini M, Mondelli M, Bertolini C, Piazzini DB, Padua L. Multicenter study of peroneal mononeuropathy: clinical, neurophysiologic, and quality of life assessment. *J Peripher Nerv Syst* 2005;10:259-268.