



## Acute Spinal Pseudoathetosis

### *Akut Spinal Psödoatetoz*

Mehmet Fevzi Öztekin, Dilara Mermi Dibek

Diskapi Yildirim Beyazit Training and Research Hospital, Clinic of Neurology, Ankara, Turkey

**Keywords:** Pseudoathetosis, multiple sclerosis clinically isolated syndrome, spinal posterior horn lesion

**Anahtar Kelimeler:** Psödoatetoz, multipl skleroz klinik izole sendrom, spinal arka horn lezyonu

#### Dear Editor,

Pseudoathetosis is an involuntary, slow, unintentional hyperkinetic movement disorder, especially in the distal extremities, due to proprioceptive sensory pathway injury (1,2). Its difference from athetosis is the increase in movement when visual stimuli are removed (1,2,3). Syringomyelia, B12 vitamin deficiency, cervical myelopathy, multiple sclerosis, myelitis, posterior cord traumas, tumors or ischemia are among the causes of pseudoathetosis (2).

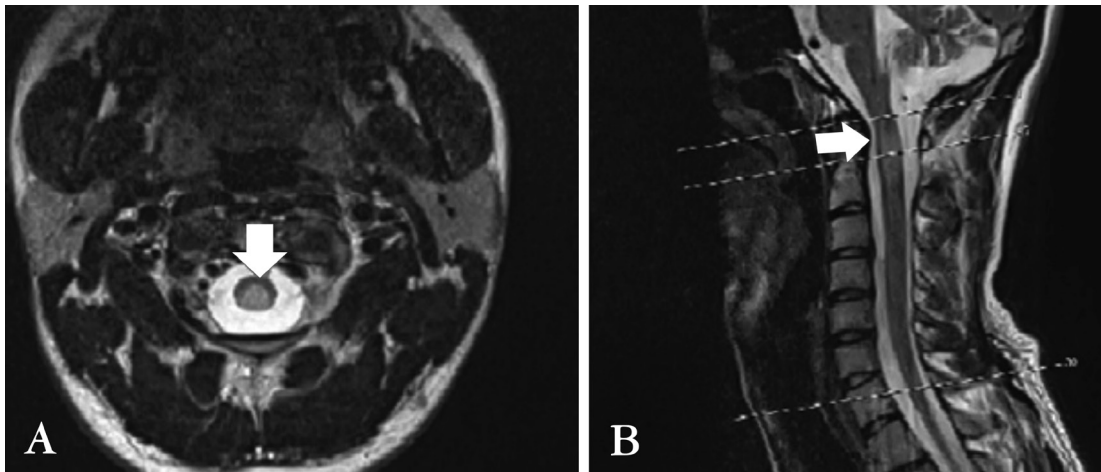
A 27-year-old, right-handed, male patient applied to our clinic with progressive numbness up to his neck, which he noticed during his watch while performing military service. He stated that his hands moved involuntarily, he felt strange while holding any object and that he could not hold a door handle or a pencil five days after the beginning of the numbness. The patient stated that he needed to hit his feet hard on the floor while walking because he could not clearly feel his steps, and that this situation had impaired his gait. His physical examination was within normal limits. On neurologic examination, the patient's general condition was good, he was conscious, cooperative, and fully oriented, he had no nuchal stiffness, and his pupils were isochoric with positive indirect and direct light reactions. The visual field was bilaterally normal; visual acuity was 20/20 bilaterally, fundus was normal bilaterally, and eye movements were free in every direction; masseter and temporalis muscle functions were normal. There

was no facial sensory deficit. He had no facial asymmetry. Rinne was bilaterally normal, Weber was in the midline, the palatal arc was equally pulled, and the uvula was in the midline. His tongue muscle strength was complete and there was no difference in height in tongue. He had no motor deficits, and superficial sensory examination revealed bilateral hypoesthesia below the 3<sup>rd</sup> and 4<sup>th</sup> cervical dermatomes. His vibration sense was significantly reduced and position sense was impaired in all extremities. The Romberg test was positive. Involuntary movements in both hands were assessed as pseudoathetosis upon involuntary movements when his eyes were closed. The cortical sensory examination was normal. The cerebellar examination was bilaterally normal. Bilateral plantar reflex responses were flexor, Hoffman was bilaterally negative, deep tendon reflexes were globally normoactive, and gait was sensory ataxic but the patient was self-mobile without support. Anal sphincter tone was normal, and there was no urinary or fecal incontinence. Cranial, cervical, and thoracic spine magnetic resonance imaging (MRI) revealed a non-enhancing, hyperintense lesion on T2-weighted sequences at the level of 2<sup>nd</sup> and 3<sup>rd</sup> cervical vertebrae in the posterior spinal cord, which extended anteriorly and posterolaterally (Figure 1A, 1B). A lumbar puncture was performed; the opening pressure was 140 mm H<sub>2</sub>O, appearance was clear, and protein level was 28 mg/dL. There were no cells. The culture was negative. Oligoclonal band was screened. Because the lesion was localized at a single location,

**Address for Correspondence/Yazışma Adresi:** Dilara Mermi Dibek MD, Diskapi Yildirim Beyazit Training and Research Hospital, Clinic of Neurology, Ankara, Turkey  
Phone: +90 553 574 56 64 E-mail: dilara\_mermi@hotmail.com ORCID ID: orcid.org/0000-0001-9963-9450

**Received/Geliş Tarihi:** 11.02.2017 **Accepted/Kabul Tarihi:** 09.07.2017

©Copyright 2017 by Turkish Neurological Society  
Turkish Journal of Neurology published by Galenos Publishing House.



**Figure 1.** A) A posterolateral hyperintense lesion at level C2-C3 on T2-weighted cervical axial magnetic resonance imaging. B) Hyperintense lesion at level C2-C3 on T2-weighted cervical sagittal magnetic resonance imaging

a MR spectroscopy (MRS) examination aiming at differential diagnosis of malignancy and demyelination was performed and the lesion was evaluated in favor of demyelination. The blood tests performed for differential diagnosis revealed normal vitamin B12 levels and negative vasculitic markers. The oligoclonal band pattern was type 2. The visual-evoked potential result was normal and somatosensory-evoked potential was prolonged. The patient was diagnosed as having clinically isolated syndrome as a result of the history, examination, and further examinations. One gram/day methylprednisolone treatment was applied for 5 days. At the end of five days, the involuntary movements in his hands were diminished and gait was normal. The patient was able to write his name easily.

Pseudoathetosis is a finding of proprioceptive deep sensory examination. It is an examination finding due to the inability of the patient to position his/her upper and lower extremities in space.

It may be confused with apraxia during neurologic examinations because the patients may not be able to position their fingers and perform skilled hand movements. However, it is distinctly different from apraxia. Apraxia is a sign of high cortical function, whereas pseudoathetosis is a deep sensory finding and their anatomic localizations are also different. It is also confused with athetosis, but the difference is that the movements increase significantly when patients close their eyes. In our case, the absence of a cortical lesion on cranial MRI, the presence of a lesion that was compatible with the deep sensory localization, the increase in the movement of the fingers when the patient closed his eyes, and accompanying deterioration in vibration and position senses suggested pseudoathetosis.

Our patient was diagnosed as having clinically isolated syndrome based on normal serum vitamin B12 level, exclusion of infectious causes in blood and cerebrospinal fluid examinations, absence of

myelopathy in cervical spinal MRI, MRS examination favoring demyelinating disease, and the presence of an oligoclonal band type 2 pattern. The recovery of pseudoathetosis with 1 gram/day corticosteroid treatment for 5 days supports our diagnosis.

Our purpose in this case report was to emphasize that the rare examination findings of pseudoathetosis should be kept in mind in daily practice because it is based on localization in the neurologic examination, and to draw attention to the importance of pseudoathetosis as much as to position and vibration senses during the deep sensory examination.

#### Ethics

**Informed Consent:** Consent form was filled out by all participants.

**Peer-review:** Internally peer-reviewed.

#### Authorship Contributions

Surgical and Medical Practices: M.F.Ö., D.M.D., Concept: M.F.Ö., D.M.D., Design: M.F.Ö., D.M.D., Data Collection or Processing: M.F.Ö., D.M.D., Analysis or Interpretation: M.F.Ö., D.M.D., Literature Search: D.M.D., Writing: D.M.D.

**Conflict of Interest:** No conflict of interest was declared by the authors.

**Financial Disclosure:** The authors declared that this study received no financial support.

#### References

1. Spitz M, Costa Machado AA, Carvalho Rdo C, Maia FM, Haddad MS, Calegario D, Scaff M, Reis Barbosa E. Pseudoathetosis: report of three patients. *Mov Disord* 2006;21:1520-1522.
2. Bray K, Chhetri SK, Varma A, Silverdale M. Reversible pseudoathetosis induced by cervical myelopathy. *Mov Disord* 2012;27:1370-1371.
3. Frank S, Barbano R. Trauma-induced spinal vascular event producing hemipseudoathetosis. *Mov Disord* 2005;20:1378-1380.