



# Colloid Cyst Causing Varying Obstructive Hydrocephalus

## *Değişken Obstrüktif Hidrosefaliye Neden Olan Kolloid Kist*

● Venkatraman Indiran<sup>1</sup>, ● Mohideen Fathima Seeni Mohamed<sup>1</sup>, ● Rengarajan Santhanam<sup>2</sup>,  
● Prabakaran Maduraimuthu<sup>1</sup>

<sup>1</sup>Sree Balaji Medical College and Hospital, Clinic of Radiodiagnosis, Tamil Nadu, India

<sup>2</sup>Sree Balaji Medical College and Hospital, Clinic of Neurosurgery, Tamil Nadu, India

**Keywords:** Brain tumors, colloid cyst, hydrocephalus  
**Anahtar Kelimeler:** Beyin tümörleri, kolloid kist, hidrosefali

Dear Editor,

A 30-year-old female presented with sudden onset of headache, for two days. She had no nausea, vomiting, memory loss, mental status changes, gait disorder or visual disturbances. She had no other medical illness. She was referred for a non-contrast computed tomography (CT) scan of head, which showed asymmetrically dilated lateral ventricles (left>right) (Figure 1A) with normal third and fourth ventricles. The right and left lateral ventricles measured ~17 and 23 mm at the trigone level, respectively. The septum pellucidum was deviated towards the right side (Figure 1B). No definite hyperdense lesion was seen at the interventricular foramen. Contrast enhanced brain magnetic resonance imaging (MRI) was performed after 20 hours, which showed mild diffuse cerebral edema and hydrocephalus with symmetric dilatation of the lateral ventricles (~1.7 cm at trigonal level) bilaterally, and periventricular interstitial edema. A small ~8-mm well-defined, rounded T1-isointense and T2-hypointense signal intensity non-enhancing lesion was seen in the region of the foramen of Monro and in the anterosuperior aspect of the third ventricle, prompting the diagnosis of colloid cyst (Figure 2). The patient was recommended to undergo surgery but she declined because her symptoms had considerably reduced.

Colloid cysts, which are benign mucin-containing cysts, account for 0.5-1.0% of primary brain tumors and are commonly found in the foramen of Monro, typically attached to the anterosuperior portion of the third ventricular roof (1). The size of

the cysts range from 3-40 mm, but even relatively small cysts can cause sudden acute hydrocephalus. Occasionally, brain herniation with rapid clinical deterioration and death may result (2). Colloid cysts originate when ectopic endodermal elements migrate into the velum interpositum during embryogenesis. The cysts are filled with viscous gelatinous material that consists of mucin, blood degradation products, foamy cells, and cholesterol crystals (1).

On CT, the density of the colloid cyst depends on its water content. Though most colloid cysts are hyperdense on CT, one-third are iso-to-hypodense (3). About 50% of colloid cysts are hyperintense on T1-weighted images, and the remainder is either isointense or hypointense with respect to brain on MRI. On T2-weighted images, most colloid cysts are hypointense to the brain (1). The paramagnetic effects of the cyst content may be responsible for the low T2 signal intensity. Isointense cysts may be difficult to identify on MR images and may be more easily seen on CT scans.

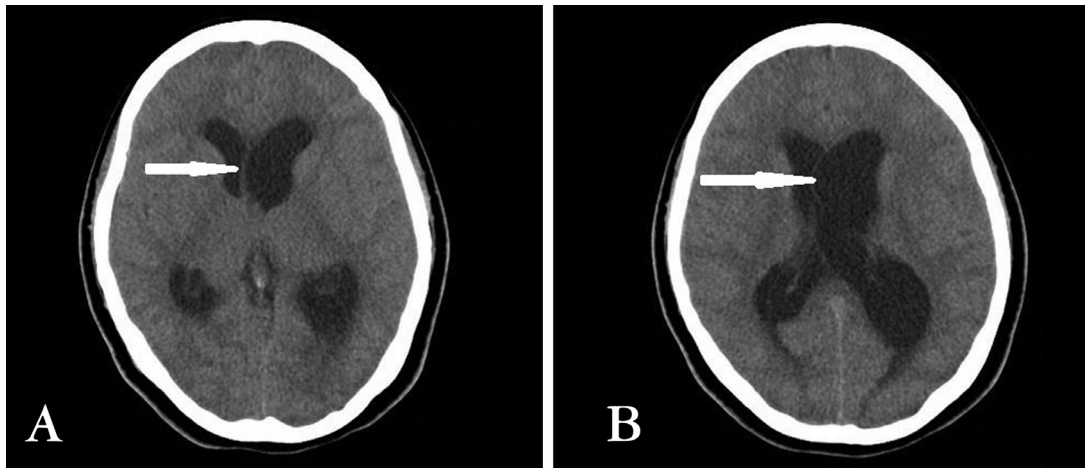
Surgical treatment of colloid cysts includes three techniques: stereotactic aspiration, endoscopic fenestration, and a microsurgical approach, the latter two are used most frequently. Cyst size, location, and their content affect the success of treatment. Some cysts may be drained completely or partially with stereotactic aspiration (4).

Although waxing and waning of symptoms due to colloid cysts has been known, radiologic demonstration of rapid change in ventricular size in a period of 24 hours has not been documented to date. Here, we have documented a significant reduction of hydrocephalus in less than 24 hours on CT and MRI imaging,

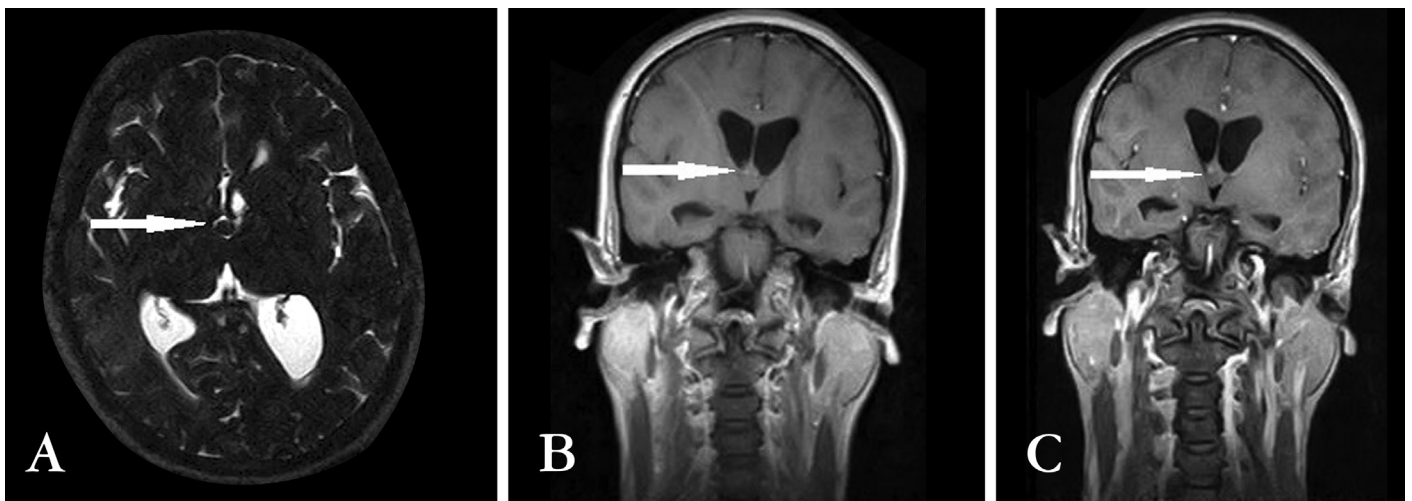
**Address for Correspondence/Yazışma Adresi:** Venkatraman Indiran MD, Sree Balaji Medical College and Hospital, Clinic of Radiodiagnosis, Tamil Nadu, India  
Phone: +90 442 265 34 29 E-mail: ivraman31@gmail.com ORCID ID: orcid.org/0000-0001-5296-0175

**Received/Geliş Tarihi:** 22.07.2017 **Accepted/Kabul Tarihi:** 02.10.2017

©Copyright 2018 by Turkish Neurological Society  
Turkish Journal of Neurology published by Galenos Publishing House.



**Figure 1.** Axial non-contrast-enhanced computed tomography image of brain at the level of lateral ventricles (A) shows asymmetrically dilated lateral ventricles (left >right). B) At trigone level shows septum pellucidum deviated towards right side and asymmetry of ventricles (left >right)



**Figure 2.** A) Axial T2 magnetic resonance imaging at level of trigone shows small T2 hypointense signal intensity lesion in the region of foramen of Monro. B, C) Coronal post contrast T1 image shows a small, well-defined, rounded non-enhancing T1 isointense lesion.

further reinforcing the fluctuant course of symptoms associated with colloid cysts.

#### Ethics

**Informed Consent:** Consent form was filled out by all participants.

**Peer-review:** Internally peer-reviewed.

#### Authorship Contributions

Surgical and Medical Practices: V.I., R.S., Concept: V.I., Design: V.I., P.M., M.F.S.M., Data Collection or Processing: V.I., P.M., Analysis or Interpretation: V.I., R.S., Literature Search: V.I., P.M., M.F.S.M., Writing: M.F.S.M., V.I.

**Conflict of Interest:** No conflict of interest was declared by the authors.

**Financial Disclosure:** The authors declared that this study received no financial support.

#### References

1. Armao D, Castillo M, Chen H, Kwok L. Colloid cyst of the third ventricle: imaging-pathologic correlation. *AJNR Am J Neuroradiol* 2000;21:1470-1477.
2. Silva D, Matis G, Chrysou O, Carvalho Junior EV, Costa L, Kitamura M, Birbilis T, Azevedo Filho H. Sudden death in a patient with a third ventricle colloid cyst. *Arq Neuropsiquiatr* 2012;70:311.
3. Algin O, Ozmen E, Arslan H. Radiologic manifestations of colloid cysts: a pictorial essay. *Can Assoc Radiol J* 2013;64:56-60.
4. Grondin RT, Hader W, MacRae ME, Hamilton MG. Endoscopic versus microsurgical resection of third ventricle colloid cysts. *Can J Neurol Sci* 2007;34:197-207.