



White Epidermoid with the “Cerebral Shading Sign” “Serebral Gölgeleme İşareti” ile Beyaz Epidermoid

© Venkatraman Indiran
IVR Scans, Chennai, India

Keywords: Epidermoid, white, shading
Anahtar Kelimeler: Epidermoid, beyaz, gölgeleme

Dear Editor,

A 24-year-old female presented with insidious onset headache, for three months. There was no history of vomiting, visual disturbances or seizures. Computed tomography (CT) showed well-defined hyperdense extra-axial lesion in right cerebellopontine angle, which appeared hyperintense on T1 and hypointense on T2-weighted images, with no contrast enhancement on magnetic resonance (MR) imaging (Figure 1). Imaging diagnosis of white epidermoid was confirmed histopathologically following sub-occipital craniectomy and excision.

Intracranial epidermoids, which are rare extra axial lesions, account for 1% of all intracranial tumors (1). Classically, epidermoid tumors are hypodense on CT scans and hypointense on T1-weighted and hyperintense on T2-weighted MR images with restricted diffusion on diffusion-weighted images. Such appearance is due to the long T1 and T2 relaxation times of

cholesterol in solid crystalline state and keratin within the cystic lesion (1).

White epidermoids are pathologically rare variants that appear hyperattenuated on CT scans. Compared with classic epidermoid cysts, the white epidermoids show reversed signal intensity on MR images, with high signal intensity on T1- and low signal intensity on T2-weighted images. High protein density, high viscosity, granulation tissue, and hemorrhage are the reasons for reversal of the usual hypodense appearance of epidermoid (1,2). The differential diagnosis for white epidermoids includes craniopharyngiomas and neurenteric cysts. Loss of signal on T2-weighted images (cerebral shading sign) has been reported only in hemorrhagic metastases and white epidermoid cysts (3). The shading sign occurs because of high viscosity, high protein concentration, and iron from recurrent hemorrhage. White epidermoids should be recognized pre-surgically to avoid the risk of chemical meningitis.

Address for Correspondence/Yazışma Adresi: Venkatraman Indiran MD, IVR Scans, Chennai, India
Phone: 04422653429 E-mail: ivraman31@gmail.com ORCID: orcid.org/0000-0001-5296-0175
Received/Geliş Tarihi: 06.02.2019 **Accepted/Kabul Tarihi:** 02.04.2019

©Copyright 2019 by Turkish Neurological Society
Turkish Journal of Neurology published by Galenos Publishing House.

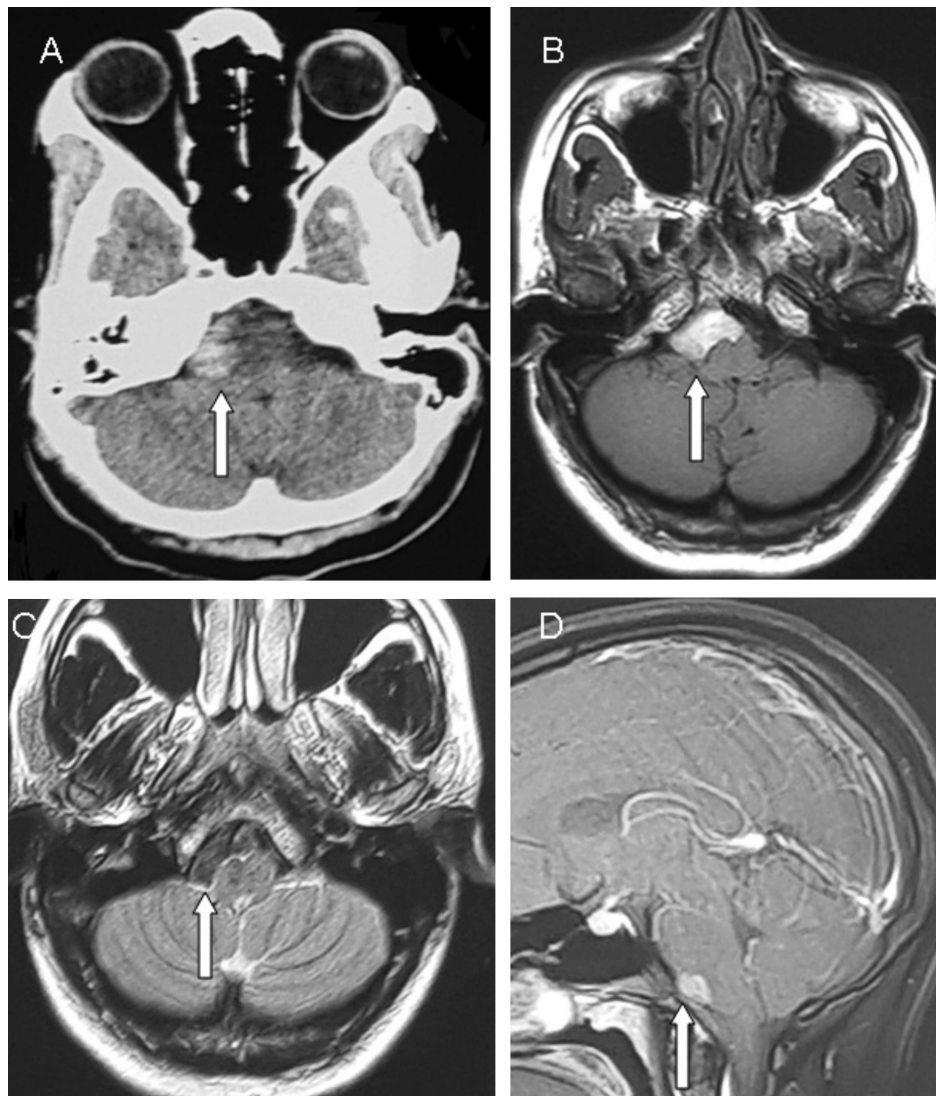


Figure 1. Computed tomography and magnetic resonance imaging of white epidermoid cyst. A) Axial computed tomography shows a well-defined hyperdense extra-axial lesion in right cerebellopontine angle. B) Axial T1-weighted magnetic resonance imaging shows a well-defined hyperintense extra-axial lesion in right cerebellopontine angle. C) Axial T2-weighted magnetic resonance imaging shows loss of signal on T2-weighted images (cerebral shading sign) in the lesion. D) Sagittal T1-weighted magnetic resonance imaging shows no contrast enhancement in the lesion

Ethics

Informed Consent: Written informed consent was taken from the parents for reporting this case.

Peer-review: Internally peer-reviewed.

Financial Disclosure: The authors declared that this study received no financial support.

References

1. Ramdasi R, Mahore A, Chagla A, Kawale J. White epidermoid at the foramen magnum. *Neurol India* 2014;62:577-579.
2. Singh SS, Gupta K, Kumaran SP, Ghosal N, Furtado SV. Pontomedullary white epidermoid: a rare cause of tinnitus. *Singapore Med J* 2012;53:179-181.
3. Puranik A, Sankhe S, Goel N, Mahore A. Cerebral shading sign in a giant intraparenchymal white epidermoid. *Neurol India* 2012;60:265-266.