Turkish Journal of Neurology

Turk J Neurol 2026;32(4):331-333
Doi: 10.55697/tnd.2026.747

LETTER TO THE EDITOR

# Isolated musculocutaneous neuropathy following video-assisted thoracoscopic sympathectomy: An electrophysiologically confirmed position-related nerve injury

**Ebru Bölük[1], Buşra Yıldız[1], Mine Kalay[2]**

[1]Department of Neurology and Clinical Neurophysiology, İzmir City Hospital, İzmir, Türkiye
[2]Department of Neurology, İzmir City Hospital, İzmir, Türkiye

Video-assisted thoracoscopic surgery is widely regarded as a safe and minimally invasive approach with low complication rates.[1] Nevertheless, neurological complications, most commonly involving the brachial plexus or long thoracic nerve, have occasionally been reported following thoracic surgical interventions.[2] In contrast, isolated peripheral mononeuropathies remain exceedingly rare. Herein, we reported a rare case of isolated musculocutaneous neuropathy after thoracoscopic sympathectomy, confirmed through electrophysiological investigations.

A 29-year-old female was referred for electrophysiological evaluation approximately three weeks after thoracoscopic sympathectomy performed for hyperhidrosis due to left elbow flexion weakness and numbness over the lateral aspect of the forearm that developed in the early postoperative period. The medical history was unremarkable for trauma or known neurological disease. Neurological examination demonstrated left biceps muscle weakness graded as 3-4/5 on the Medical Research Council scale, diminished left biceps tendon reflex, and hypoesthesia over the lateral aspect of the forearm, whereas shoulder abduction, elbow extension, wrist movements, and intrinsic hand muscle strength were preserved. A written informed consent was obtained from the patient.

Initial nerve conduction studies demonstrated normal sensory and motor conduction parameters of the median, ulnar, and radial nerves. However, the musculocutaneous motor compound muscle action potential (CMAP) amplitude recorded from the left biceps brachii muscle was reduced compared to the contralateral side (3.5 mV *vs.* 6.0 mV). In addition, the sensory nerve action potential (SNAP) amplitude of the left lateral antebrachial cutaneous nerve was mildly reduced relative to the opposite side, while other examined sensory and motor nerves were within normal limits (Table 1). Needle electromyography demonstrated fibrillation potentials and positive sharp waves confined to the left biceps brachii muscle, accompanied by reduced recruitment and chronic neurogenic motor unit potential changes, whereas muscles representing adjacent axillary, radial, ulnar, and median nerve territories were normal. Representative bilateral musculocutaneous CMAP recordings following Erb's point stimulation demonstrated marked amplitude reduction on the affected side (Figure 1). These electrophysiological findings were considered consistent with isolated musculocutaneous neuropathy with partial axonal involvement.

Musculocutaneous neuropathy is a rare peripheral mononeuropathy that most commonly develops secondary to traction, compression,

**Correspondence:** Ebru Bölük, MD. İzmir Şehir Hastanesi, Nöroloji ve Klinik Nörofizyoloji Kliniği, 35530 Bayraklı, İzmir, Türkiye.
**E-mail:** ekabukcu@gmail.com
**Received:** June 02, 2026 **Accepted:** July 22, 2026 **Published online:** September 10, 2026
**Cite this article as:** Bölük E, Yıldız B, Kalay M. Isolated musculocutaneous neuropathy following video-assisted thoracoscopic sympathectomy: An electrophysiologically confirmed position-related nerve injury. Turk J Neurol 2026;32(4):331-333. doi: 10.55697/tnd.2026.747.

© Copyright 2026 by the Turkish Neurological Society. This work is licensed under the Creative Commons Attribution-NonCommercial-NoDerivatives 4.0 International License (CC BY-NC-ND 4.0). To view a copy of this license, visit https://creativecommons.org/licenses/by-nc-nd/4.0/

**TABLE 1**
Motor and sensory nerve conduction study findings

| Nerve | Side | Stimulation site | Latency (ms) | Amplitude | Conduction velocity (m/s) |
|---|---|---|---|---|---|
| Musculocutaneous (Biceps) | Right | Erb's point | 3.0 | 6.0 mV | - |
| | Left | Erb's point | 3.2 | **3.5 mV** | - |
| Ulnar (ADM) | Right | Wrist | 2.6 | 19.3 mV | - |
| | | Elbow | 6.0 | 18.9 mV | 69.1 |
| | Left | Wrist | 2.6 | 17.7 mV | - |
| | | Elbow | 5.8 | 17.8 mV | 71.3 |
| Median (APB) | Right | Wrist | 3.0 | 26.1 mV | - |
| | | Elbow | 6.8 | 24.7 mV | 66.4 |
| | Left | Wrist | 2.9 | 22.1 mV | - |
| | | Elbow | 7.2 | 21.3 mV | 62.7 |
| Lateral antebrachial cutaneous | Right | - | 1.3 | 10.1 µV | 60.5 |
| | Left | - | 1.4 | **6.6 µV** | 56.3 |
| Superficial radial | Right | - | 1.9 | 45.0 µV | 61.2 |
| | Left | - | 1.2 | 41.6 µV | 66.7 |
| Median digital I | Right | - | 1.8 | 70.2 µV | 68.8 |
| | Left | - | 1.9 | 63.5 µV | 63.5 |
| Ulnar digital V | Right | - | 2.2 | 60.2 µV | 62.5 |
| | Left | - | 2.1 | 67.3 µV | 59.0 |

ADM, abductor digiti minimi; APB, abductor pollicis brevis; CMAP, compound muscle action potential; SNAP, sensory nerve action potential. Motor amplitudes were measured peak-to-peak and sensory amplitudes baseline-to-peak. Electrophysiological evaluation demonstrates reduced musculocutaneous CMAP amplitude together with decreased lateral antebrachial cutaneous SNAP amplitude on the affected side, while other examined nerves were within normal limits, supporting localization to isolated musculocutaneous neuropathy.

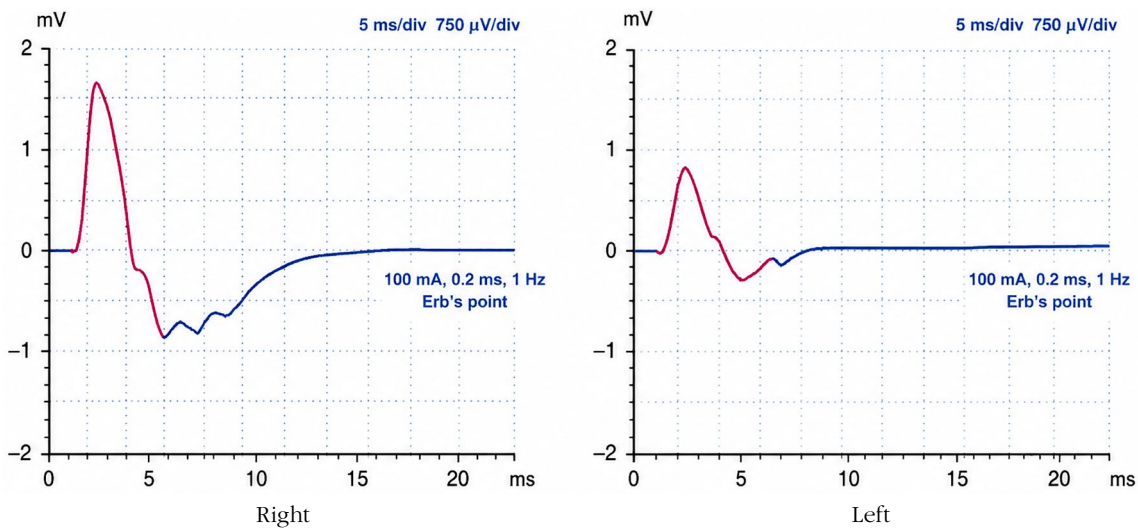


**Figure 1.** Compound muscle action potentials recorded from the biceps brachii following Erb's point stimulation demonstrating reduced amplitude on the left side compared with the right.

or repetitive mechanical stress.[3] Previously reported musculocutaneous neuropathies have predominantly been associated with sports-related traction injuries or prolonged positioning.[3,4] Likewise, peripheral nerve complications following thoracic surgical procedures, particularly involving the long thoracic nerve, have also been documented.[2] However,

isolated musculocutaneous neuropathy following thoracoscopic sympathectomy has not, to the best of our knowledge, been previously reported.

Surgical positioning represents a well-recognized mechanism of perioperative peripheral nerve injury. During video-assisted thoracoscopic surgery, patients are typically placed in the lateral decubitus position with the upper extremity maintained in abduction, which may predispose the musculocutaneous nerve to traction injury, particularly at anatomically vulnerable segments around the coracobrachialis muscle. In the present case, the close temporal relationship between surgery and symptom onset, together with electrophysiological findings demonstrating isolated involvement of the musculocutaneous nerve, strongly supports a position-related neuropathic mechanism.[4]

Electrophysiological evaluation played a pivotal role in lesion localization. The reduction in musculocutaneous CMAP amplitude, accompanied by active denervation confined to the biceps brachii muscle and preservation of findings in muscles innervated by adjacent nerves, provided objective evidence of partial axonal involvement while supporting exclusion of a more extensive brachial plexus lesion. Similarly, the value of electrophysiological investigations in objectively localizing rare neurological lesions has been highlighted in previously reported uncommon neuropathic presentations.[5]

Therefore, this case highlights the importance of considering isolated peripheral mononeuropathies, in addition to brachial plexus injury, in patients presenting with postoperative upper extremity weakness following thoracic surgery.

**Author Contributions:** E.B., B.Y., M.K.: Conceptualization, study design; E.B.: Electrophysiological evaluation and clinical management, data acquisition, analysis and interpretation, literature review, manuscript drafting; Critical revision of the manuscript: All authors.

**Conflict of Interest:** The authors declared no conflicts of interest with respect to the authorship and/or publication of this article.

**Funding:** The authors received no financial support for the research and/or authorship of this article.

**AI Disclosure:** The authors declare that artificial intelligence (AI) tools were not used, or were used solely for language editing, and had no role in data analysis, interpretation, or the formulation of conclusions. All scientific content, data interpretation, and conclusions are the sole responsibility of the authors. The authors further confirm that AI tools were not used to generate, fabricate, or 'hallucinate' references, and that all references have been carefully verified for accuracy.

## REFERENCES

1. Ersin OE, Yanik F, Karamustafaoglu YA, Yoruk Y. The effects of sympathectomy ganglion levels on late complications in the treatment of hyperhidrosis. J Minim Access Surg 2025;21:175-82. doi: 10.4103/jmas.jmas_75_24.
2. Isono T, Mori S, Kusumoto H, Shiono H. Winged scapula following axillary thoracotomy with long thoracic nerve preservation. BMJ Case Rep 2020;13:e232970. doi: 10.1136/bcr-2019-232970.
3. Vineyard AP, Gallucci AR, Imbus SR, Garrison JC, Conway JE. Residents case report: Musculocutaneous nerve injury in a collegıate baseball pitcher. Int J Sports Phys Ther 2020;15:804-13. doi: 10.26603/ijspt20200804.
4. Mano T, Fujimura S. Brachial plexus injury and musculocutaneous nerve palsy during prone positioning in a patient with COVID-19. Cureus 2022;14:e24931. doi: 10.7759/cureus.24931.
5. Bölük E, Çoban Taşkın A. Cerebellopontine angle schwannoma presenting with Vernet syndrome: A rare case confirmed by electrophysiological findings. Turk J Neurol 2026;32(1):92-4. doi: 10.55697/tnd.2026.516.