Turkish Journal of Neurology

Turk J Neurol 2026;32(4):323-328
Doi: 10.55697/tnd.2026.647

LETTER TO THE EDITOR

Eosinophilic granulomatosis with polyangiitis presenting with concurrent acute polyneuropathy, acute myocarditis, and acute interstitial lung disease

Memet Aslanyavrusu[1], Fahrettin Ege[2], Gülhan Sarıçam[3]

[1]Department of Neurology, Kayseri City Hospital, Kayseri, Türkiye
[2]Department of Neurology, Yüksek İhtisas University, Ankara, Türkiye
[3]Department of Neurology, Ankara Pursaklar State Hospital, Ankara, Türkiye

Polyneuropathies are characterized by diffuse involvement of the peripheral nervous system and may affect motor, sensory, or autonomic nerve fibers. Clinical manifestations vary widely and include muscle weakness, atrophy, paresthesia, neuropathic pain, hypoesthesia, and autonomic symptoms.[1] The etiology of polyneuropathies is broad, encompassing metabolic, infectious, immunological, toxic, hereditary, and paraneoplastic causes.[2] While diabetes mellitus is the most common cause of chronic polyneuropathy worldwide, the most frequent cause of acute-onset polyneuropathy is Guillain-Barré syndrome (GBS), an immune-mediated acute inflammatory polyradiculoneuropathy.[3] However, acute polyneuropathies secondary to vasculitic processes are of particular clinical importance due to their rapid progression and potential to cause severe functional impairment, underscoring the need for early diagnosis and prompt treatment.[4]

First described by Churg and Strauss[5] in 1951, eosinophilic granulomatosis with polyangiitis (EGPA) is a rare systemic necrotizing vasculitis affecting small- to medium-sized vessels and is typically characterized by asthma, peripheral eosinophilia, and multisystem involvement. The estimated annual incidence of EGPA ranges from 0.5 to 4.2 cases per million individuals.[6] The disease most commonly begins with asthma-related respiratory symptoms and may subsequently progress to involve vital organs, including the peripheral nervous system, cardiac structures, gastrointestinal tract, and lung parenchyma. Among these manifestations, peripheral neuropathy and myocarditis are considered the most important determinants of prognosis.[7]

In EGPA, in which eosinophilic inflammation and vasculitic processes act concomitantly, simultaneous multiorgan involvement is uncommon but may pose significant diagnostic challenges. Therefore, new classification criteria for EGPA based on a weighted scoring system were published in 2022 by the American College of Rheumatology and the European Alliance of Associations for Rheumatology. In this scoring system, clinical and laboratory features, including peripheral eosinophilia, the presence of asthma, nasal polyposis, mononeuropathy or polyneuropathy, antineutrophil cytoplasmic antibody (ANCA) positivity, and biopsy-proven extravascular eosinophilic inflammation, are assigned different weights, and a total score of ≥ 6 is considered sufficient for the classification of EGPA. By emphasizing eosinophilic inflammation and upper airway involvement, these updated criteria provide improved sensitivity and specificity for distinguishing EGPA from other ANCA-associated vasculitides, as well as from acute inflammatory neuropathies.[8]

Correspondence: Memet Aslanyavrusu, MD. Kayseri Şehir Hastanesi, Nöroloji Kliniği, 38080 Kocasinan, Kayseri, Türkiye.
E-mail: aslanyavrusu@yahoo.com
Received: January 18, 2026 **Accepted:** April 01, 2026 **Published online:** June 03, 2026
Cite this article as: Aslanyavrusu M, Ege F, Sarıçam G. Eosinophilic granulomatosis with polyangiitis presenting with concurrent acute polyneuropathy, acute myocarditis, and acute interstitial lung disease. Turk J Neurol 2026;32(4):323-328. doi: 10.55697/tnd.2026.647.

© Copyright 2026 by the Turkish Neurological Society. This work is licensed under the Creative Commons Attribution-NonCommercial-NoDerivatives 4.0 International License (CC BY-NC-ND 4.0). To view a copy of this license, visit https://creativecommons.org/licenses/by-nc-nd/4.0/

Peripheral nervous system involvement is common in EGPA, with neurological manifestations occurring in approximately 50 to 75% of patients, particularly during the early vasculitic phase of the disease. Neuropathy is typically severe, sensorimotor in nature, and electrophysiologically consistent with axonal damage, most often presenting as mononeuritis multiplex. However, less frequently, symmetric or asymmetric acute polyneuropathy, sensory deficits, and neuropathic pain may also occur.[9] The coexistence of peripheral neuropathy with cardiac and pulmonary involvement is considered an important clinical indicator of disease severity and prognosis.[10] In this context, EGPA cases presenting with the simultaneous development of acute polyneuropathy, myocarditis, and interstitial lung disease are exceedingly rare and clinically noteworthy due to the critical role of early diagnosis and appropriate treatment in determining outcomes. In this report, we presented a rare case of EGPA initially manifesting as acute symmetric polyneuropathy, followed shortly by the development of acute myocarditis and acute interstitial lung disease.

A 44-year-old male with a medical history of allergic asthma and chronic sinusitis with nasal polyposis was admitted to the clinic with progressively worsening gait difficulty over the preceding seven to 10 days. Neurological examination revealed symmetric motor weakness graded as 4/5 in all extremities, more pronounced distally, along with hypoactive deep tendon reflexes. No sensory deficits, sphincter dysfunction, or pathological reflexes were observed.

Initially, electrophysiological studies were performed with a preliminary diagnosis of GBS and demonstrated findings consistent with severe, symmetric sensorimotor axonal polyneuropathy on nerve conduction studies (Tables 1, 2). Lumbar puncture was performed on the 10th day after symptom onset. Cerebrospinal fluid (CSF) analysis revealed a protein level of 20.6 mg/dL and a normal cell count. The white blood cell count was 25.15 × 10^9/µL, with eosinophils accounting for 38.4% of leukocytes, corresponding to an absolute eosinophil count of approximately 9.65 × 10^9/µL. The C-reactive protein level was markedly elevated at 148.7 mg/L. In light of these findings, the initial suspicion of GBS was reconsidered, and acute vasculitic polyneuropathy secondary to EGPA was considered the leading diagnosis.

TABLE 1
Motor nerve conduction study findings at presentation

Nerve / stimulation site	Distal latency (ms)	Amplitude (mV)	Area (mVms)	Interval (ms)	NCV (m/s)	F-wave latency
Median (left)						
Wrist	4.02	1.07	2.65	4.02		NP
Elbow	NP					
Ulnar (left)						
Wrist	3.36	2.47	8.20	3.06		NP
Elbow distal	NP					
Median (right)						
Wrist	NP					
Ulnar (right)						
Wrist	3.04	2.37	6.81	3.04		NP
Elbow distal	NP					
Tibial (left)						
Ankle	4.95	0.880	1.54	4.95		NP
Popliteal	NP					
Peroneal (left)						
Ankle	3.55	0.770	1.83	3.55		NP
Caput fibula	NP					
Tibial (right)						
Ankle	NP					
Peroneal (right)						
Ankle	NP					

NCV, nerve conduction velocity; NP, no potential.

TABLE 2
Sensory nerve conduction study findings

Nerve/stimulation site	Distal latency (ms)	Amplitude (mV)	Area (mVms)	Interval (ms)	NCV (m/s)
Median (left)					
Second finger	3.1	8.60	0.35	3.10	48.4
Palm	2.1	28.10	1.43	2.10	41.4
Ulnar (left)					
Fifth finger	2.86	8.30	0.74	2.86	45.5
Median (right)					
Second finger	3.32	16.90	0.10	3.32	45.2
Palm	2.18	18.10	0.90	2.18	39.0
Ulnar (right)					
Fifth finger	2.96	11.40	0.20	2.96	44.9
Sural (left)	NP				
Sural (right)	NP				

NCV, nerve conduction velocity; NP, no potential.

Approximately 6 h after hospital admission, the patient experienced sudden clinical deterioration, with the onset of tachycardia and a marked decline in oxygen saturation to 75 to 80%. Transthoracic echocardiography revealed severe hypokinesia of the inferior wall and apex of the left ventricle. Cardiac biomarkers were markedly elevated, with creatine kinase of 4768 U/L, N-terminal pro-B-type natriuretic peptide of 6931.1 pg/mL, and troponin I > 50,000 ng/mL. Acute coronary syndrome was considered in the differential diagnosis; however, coronary computed tomography (CT) angiography did not reveal significant coronary artery stenosis. In conjunction with the clinical context, these findings were considered more consistent with acute myocarditis than with ischemic etiology. Chest CT demonstrated bilateral ground-glass opacities predominantly involving the posterior and peripheral regions of both lungs. These opacities were accompanied by peribronchovascular interstitial thickening. No areas of consolidation or pleural effusion were observed. In addition, small nonspecific lymph nodes measuring < 10 mm in short-axis diameter were detected in the paratracheal, aortopulmonary, and bilateral hilar regions. In the clinical context of marked eosinophilia and systemic EGPA findings, these radiologic features were considered compatible with pulmonary involvement related to EGPA. Paranasal sinus CT revealed diffuse nasal and paranasal sinus polyposis (Figures 1, 2).

Due to the need for close cardiac monitoring and continuous positive airway pressure support, the patient was transferred to the intensive care unit. At 24 h of intensive care follow-up, serum immunoglobulin E (IgE) level was 199.2 IU/mL, and perinuclear ANCA level was 143.0 IU/mL. Based on the integrated evaluation of clinical, laboratory, and imaging findings, the patient was diagnosed with concurrent acute vasculitic polyneuropathy, acute myocarditis, and acute interstitial lung disease secondary to EGPA.

Given the severe and rapidly progressive course of the disease, a more aggressive immunosuppressive treatment was initiated,

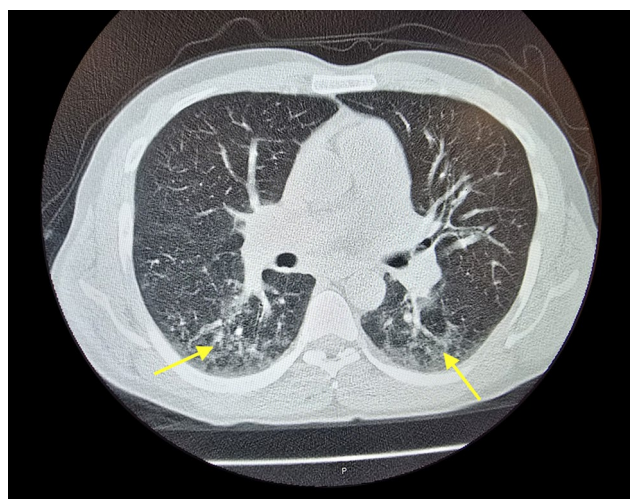

Figure 1. Axial chest CT image demonstrating bilateral basal-predominant ground-glass opacities and patchy interstitial infiltrates (arrows), consistent with acute interstitial lung involvement in EGPA.

CT, computed tomography; EGPA, eosinophilic granulomatosis with polyangiitis.



Figure 2. Axial paranasal sinus CT image demonstrating diffuse mucosal thickening and soft-tissue opacification involving the maxillary and ethmoid sinuses (arrows), consistent with nasal polyposis and chronic rhinosinusitis related to EGPA.

CT, computed tomography; EGPA, eosinophilic granulomatosis with polyangiitis.

consisting of pulse methylprednisolone (1,000 mg/day) for seven days and high-dose induction cyclophosphamide administered at a total dose of 40 mg/kg divided over five days. From the third day of treatment onward, marked clinical improvement was observed, with normalization of oxygen saturation and resolution of peripheral eosinophilia. By the seventh day of therapy, cardiac biomarkers had also returned to normal ranges.

On the final neurological examination, muscle strength in the upper extremities had substantially improved, whereas mild paresis persisted in the lower extremities. At discharge, lower extremity muscle strength was graded as 4/5 according to the Medical Research Council scale in both proximal and distal muscle groups. However, the patient was unable to ambulate independently without assistance at that time (Functional Ambulation Category, 3-4). The patient was discharged with a planned intermittent cyclophosphamide regimen at a prophylactic dose of 5 mg/kg. At the three-month follow-up, significant clinical improvement was observed, and the patient was able to ambulate independently without support (Functional Ambulation Category, 5), with near-complete recovery of motor function.

This case is noteworthy for illustrating a rare presentation of EGPA characterized by concurrent acute vasculitic polyneuropathy, acute myocarditis, and acute interstitial lung disease. In our patient, the initial symptom of acute-to-subacute gait disturbance, together with electrophysiological findings of severe, symmetric axonal sensorimotor polyneuropathy, initially suggested GBS. However, the presence of marked eosinophilia, markedly elevated inflammatory markers, normal cerebrospinal fluid biochemistry, and a history of asthma and nasal polyposis shifted the differential diagnosis toward EGPA. The subsequent rapid development of cardiac and pulmonary involvement demonstrated that the disease can simultaneously affect not only the peripheral nervous system but also multiple life-threatening organ systems. In this respect, our case highlights the diagnostic challenges posed by EGPA in its early vasculitic phase, during which it may mimic acute inflammatory neuropathies, and underscores the importance of heightened clinical awareness given its potential for rapid multisystem progression.

Polyneuropathy is one of the typical neurological manifestations of EGPA and is included among the diagnostic criteria of the disease. Polyneuropathy associated with EGPA is most commonly characterized by axonal degeneration occurring in the absence of CSF biochemical abnormalities. Necrotizing vasculitis with vascular occlusion plays a central role in the pathogenesis of neuropathy, which in many cases becomes clinically apparent before the development of overt multiorgan involvement. Although axonal polyneuropathy represents the most frequent electrophysiological pattern in EGPA, cases with accompanying demyelinating features were also reported in the literature.[11] However, in our patient, the electrophysiologic pattern appeared symmetric. One possible explanation is that a rapidly progressive vasculitic process may initially cause multifocal axonal injury, which can subsequently become confluent and produce a seemingly symmetric electrophysiologic pattern. In the present case, the acute-to-subacute clinical course, marked eosinophilia, elevated inflammatory markers, and the simultaneous presence of cardiac

and pulmonary involvement were consistent with active systemic EGPA. Therefore, the overall findings were considered more compatible with a rapidly progressive vasculitic neuropathy rather than a slowly progressive length-dependent distal axonopathy. Nevertheless, the possibility of a purely length-dependent axonal process cannot be completely excluded based solely on electrophysiologic findings. De Toni Franceschini et al.[12] reported a fatal case of EGPA with prominent cranial nerve involvement in which polyneuropathy was the initial clinical manifestation.

Central nervous system involvement in EGPA most commonly presents as ischemic lesions related to vasculitis, eosinophil-mediated toxicity, or cardiac embolism.[13] In addition to peripheral neuropathy, other neurological manifestations such as cranial neuropathies, spinal cord involvement, and optic neuropathy were also reported.[14] However, no clinical or radiological evidence of central nervous system involvement was observed in our patient. A written informed consent was obtained from the patient.

In conclusion, this case demonstrates that EGPA may present in the early stage with acute or subacute-onset polyneuropathy and that life-threatening cardiac and pulmonary involvement can develop rapidly and concurrently. Although the initial clinical and electrophysiological findings may suggest GBS, the presence of marked eosinophilia, elevated inflammatory markers, normal CSF findings, and a history of asthma and nasal polyposis support a diagnosis of EGPA. Eosinophilic granulomatosis with polyangiitis should be strongly considered in cases of acute polyneuropathy accompanied by eosinophilia and an atopic background, and early close monitoring for cardiac and pulmonary involvement is essential.

Author Contributions: M.A.: Concept, data collection, writing the article; M.A., F.E.: Design, analysis and interpretation; M.A., G.S.: Literature review; F.E., G.S.: Critical review.

Conflict of Interest: The authors declared no conflicts of interest with respect to the authorship and/or publication of this article.

Funding: The authors received no financial support for the research and/or authorship of this article.

AI Disclosure: The authors declare that artificial intelligence (AI) tools were not used, or were used solely for language editing, and had no role in data analysis, interpretation, or the formulation of conclusions. All scientific content, data interpretation, and conclusions are the sole responsibility of the authors. The authors further confirm that AI tools were not used to generate, fabricate, or 'hallucinate' references, and that all references have been carefully verified for accuracy.

REFERENCES

1. Ducci RD, Tessaro CL, Kay CSK, Fustes OJH, Werneck LC, Lorenzoni PJ, et al. Peripheral polyneuropathy from electrodiagnostic tests: A 10-year etiology and neurophysiology overview. Arq Neuropsiquiatr 2022;80:270-9. doi: 10.1590/0004-282X-ANP-2020-0561.
2. Ziegler D, Tesfaye S, Spallone V, Gurieva I, Al Kaabi J, Mankovsky B, et al. Screening, diagnosis and management of diabetic sensorimotor polyneuropathy in clinical practice: International expert consensus recommendations. Diabetes Res Clin Pract 2022;186:109063. doi: 10.1016/j.diabres.2021.109063.
3. Aslanyavrusu M, Ege F, Sarıçam G. Monocytes and systemic inflammation in Guillain-Barré syndrome: Subtypes and relationship with prognosis. Turk J Neurol 2025;31:334-0. doi: 10.55697/tnd.2025.508.
4. Kapoor M, Reddel SW. Ways to think about vasculitic neuropathy. Curr Opin Neurol 2024;37:478-86. doi: 10.1097/WCO.0000000000001301.
5. Churg J, Strauss L. Allergic granulomatosis, allergic angiitis, and periarteritis nodosa. Am J Pathol 1951;27:277-301.
6. Lane SE, Watts R, Scott DG. Epidemiology of systemic vasculitis. Curr Rheumatol Rep 2005;7:270-5. doi: 10.1007/s11926-005-0036-5.
7. Gioffredi A, Maritati F, Oliva E, Buzio C. Eosinophilic granulomatosis with polyangiitis: An overview. Front Immunol 2014;5:549. doi: 10.3389/fimmu.2014.00549.
8. Grayson PC, Ponte C, Suppiah R, Robson JC, Craven A, Judge A, et al. 2022 American College of Rheumatology/European Alliance of Associations for Rheumatology Classification Criteria for Eosinophilic Granulomatosis with Polyangiitis. Ann Rheum Dis 2022;81:309-14. doi: 10.1136/annrheumdis-2021-221794.
9. Cattaneo L, Chierici E, Pavone L, Grasselli C, Manganelli P, Buzio C, et al. Peripheral neuropathy in Wegener's granulomatosis, Churg-Strauss syndrome and microscopic polyangiitis. J Neurol Neurosurg Psychiatry 2007;78:1119-23. doi: 10.1136/jnnp.2006.111013.
10. Comarmond C, Pagnoux C, Khellaf M, Cordier JF, Hamidou M, Viallard JF, et al. Eosinophilic granulomatosis with polyangiitis (Churg-Strauss): Clinical characteristics and long-term followup of the 383 patients enrolled in the French Vasculitis Study Group cohort. Arthritis Rheum 2013;65:270-81. doi: 10.1002/art.37721.
11. Pati AR, Capecchi PL, Malandrini A, Federico A, Mignarri A. Polyneuropathy with demyelinating changes in Churg-Strauss syndrome: An unusual association. Neurol Sci 2017;38:695-7. doi: 10.1007/s10072-016-2789-1.

12. De Toni Franceschini L, Amadio S, Scarlato M, Fazio R, Quattrini A, Dell'antonio G, et al. A fatal case of Churg-Strauss syndrome presenting with acute polyneuropathy mimicking Guillain-Barré syndrome. Neurol Sci 2011;32:937-40. doi: 10.1007/s10072-011-0591-7.
13. André R, Cottin V, Saraux JL, Blaison G, Bienvenu B, Cathebras P, et al. Central nervous system involvement in eosinophilic granulomatosis with polyangiitis (Churg-Strauss): Report of 26 patients and review of the literature. Autoimmun Rev 2017;16:963-9. doi: 10.1016/j.autrev.2017.07.007.
14. Gomes I, Girão A, Gomes J, Rebelo O, Jesus-Ribeiro J. Neurological impact of eosinophilic granulomatosis with polyangiitis. Acta Neurol Belg 2022;122:123-8. doi: 10.1007/s13760-021-01683-5.