Turkish Journal of Neurology

Turk J Neurol 2026;32(4):318-322
Doi: 10.55697/tnd.2026.665

LETTER TO THE EDITOR

Apparent nigral sparing and an eye-of-the-tiger-like pallidal pattern in mitochondrial membrane protein-associated neurodegeneration

Alpkağan Kale, **İdris Şevki Köken**

Department of Neurology, Balıkesir University Faculty of Medicine, Balıkesir, Türkiye

A 23-year-old female presented with progressive gait impairment and dysphagia. Frequent falls began at age 10 years, followed by progressive dysarthria, dysphagia, cognitive decline, urinary and fecal incontinence, and loss of independent ambulation. Examination showed cognitive impairment, dysarthria, marked lower-limb spasticity and rigidity, Medical Research Council grade 3/5 weakness, bilateral extensor plantar responses, and mixed rest and action tremor of the hands. Nerve conduction studies/electromyography supported peripheral neuropathy; ammonia, iron indices, copper, and ceruloplasmin were unremarkable. The parents were nonconsanguineous. The 55-year-old mother and 56-year-old father were neurologically normal on targeted assessment of gait, spasticity, parkinsonism, dystonia, tremor, cognition/psychiatric features, optic atrophy, and peripheral neuropathy. They declined genetic testing because they were asymptomatic. A paternal uncle's 16-year-old daughter and another paternal uncle's 17-year-old son reportedly had recurrent falls, progressive limb weakness, imbalance, and cognitive regression; they were unavailable for examination or testing. The mother has six siblings and the father nine, but extended family histories were unavailable (Figure 1). A written informed consent was obtained from the patient.

Brain magnetic resonance imaging at 1.5 T showed symmetric globus pallidus hypointensity on T2-weighted images and corresponding susceptibility-related pallidal hypointensity/blooming, with central pallidal hyperintensity tracking the medial medullary lamina and producing an eye-of-the-tiger-like, or pallidal-splitting, appearance (Figure 2). In contrast, dedicated axial T2-weighted and susceptibility-weighted sections of the midbrain showed no definite pathologic bilateral substantia nigra hypointensity or blooming; T1-weighted and fluid-attenuated inversion recovery images showed no corresponding focal abnormality (Figure 3). The formal neuroradiology report concurred that no definite nigral signal abnormality was present on the available sequences. Therefore, we describe apparent nigral sparing rather than normal iron content, as subtle deposition below the sensitivity of conventional 1.5-T imaging cannot be excluded without quantitative susceptibility mapping or R2* relaxometry.

Solo whole-exome sequencing identified a homozygous C19orf12 variant, establishing a molecular diagnosis of mitochondrial membrane protein-associated neurodegeneration (MPAN). The MANE Select nomenclature is NM_031448.6:c.161G>T, p.(Gly54Val), rs752450983; the 2017 report used NM_001031726.2:c.194G>T, p.(Gly65Val). No additional reportable variant was identified in other adequately covered neurodegeneration with brain iron accumulation genes, including PANK2. Reassessment under American College of Medical Genetics and

Correspondence: Alpkağan Kale, MD. Balıkesir Üniversitesi Tıp Fakültesi, Nöroloji Anabilim Dalı, 10145 Altıeylül, Balıkesir, Türkiye
E-mail: dralpkagankale@gmail.com
Received: February 13, 2026 **Accepted:** August 10, 2026 **Published online:** September 10, 2026
Cite this article as: Kale A, Köken İŞ. Apparent nigral sparing and an eye-of-the-tiger-like pallidal pattern in mitochondrial membrane protein-associated neurodegeneration. Turk J Neurol 2026;32(4):318-322. doi: 10.55697/tnd.2026.665.

© Copyright 2026 by the Turkish Neurological Society. This work is licensed under the Creative Commons Attribution-NonCommercial-NoDerivatives 4.0 International License (CC BY-NC-ND 4.0). To view a copy of this license, visit https://creativecommons.org/licenses/by-nc-nd/4.0/

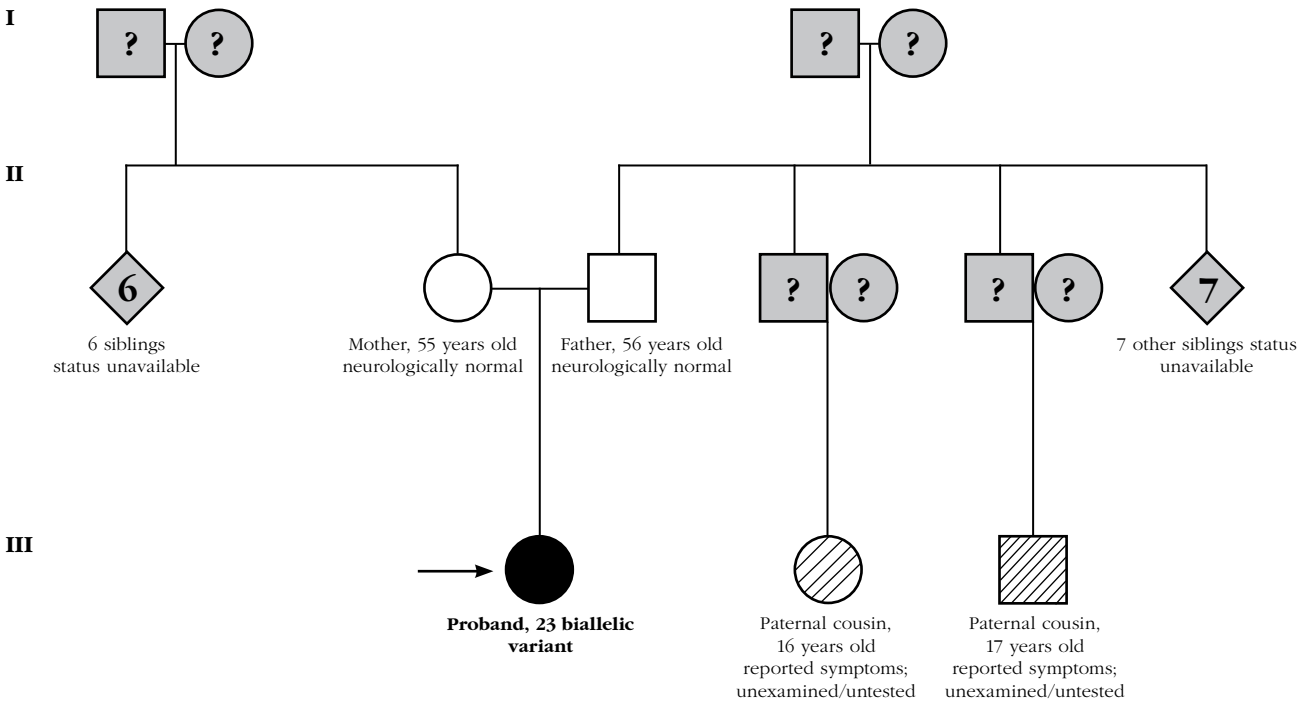

Figure 1. Pedigree and limits of inheritance assessment. The proband has genetically confirmed mitochondrial membrane protein-associated neurodegeneration. Both nonconsanguineous parents were clinically normal on directed neurologic examination but declined genetic testing; therefore, carrier status could not be demonstrated. Two paternal cousins were reported by relatives to have similar progressive neurologic symptoms but were unavailable for examination or testing and are not assigned this diagnosis. Other relatives' clinical and genetic status was unavailable. The proband's biallelic genotype and unaffected parents favor autosomal recessive inheritance, but the pedigree does not establish segregation. Squares indicate males, circles females, diamonds unspecified sex, an arrow the proband, solid fill genetically confirmed disease, diagonal hatching reportedly affected but unverified status, and gray fill unavailable clinical/genetic status.

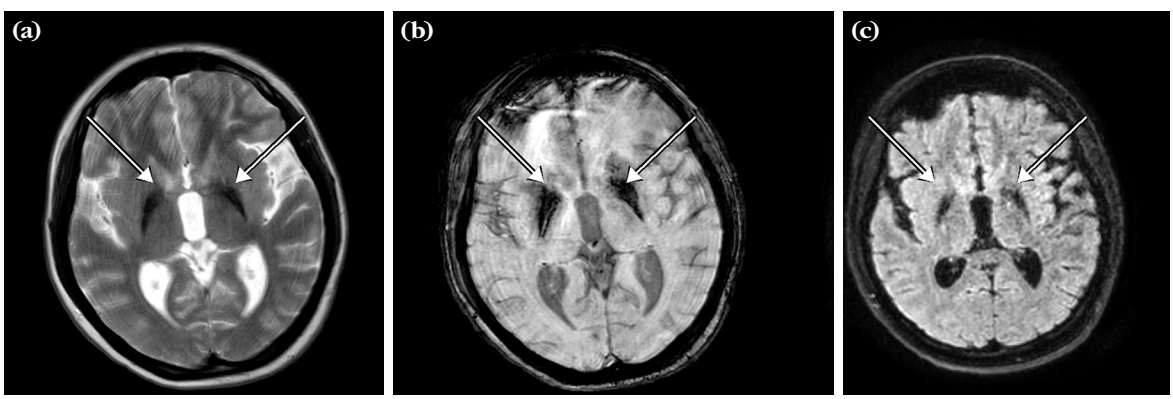

Figure 2. Pallidal-predominant iron deposition and an eye-of-the-tiger-like pattern. All images were acquired at 1.5 T. **(a)** Axial T2-weighted image shows symmetric globus pallidus hypointensity with a central hyperintense component corresponding to the medial medullary lamina, producing pallidal splitting. **(b)** Axial susceptibility-weighted image shows marked bilateral pallidal susceptibility blooming. **(c)** Axial fluid-attenuated inversion recovery image provides anatomic correlation and demonstrates the central pallidal hyperintense component. No substantia nigra inference is made from these pallidal-level sections.

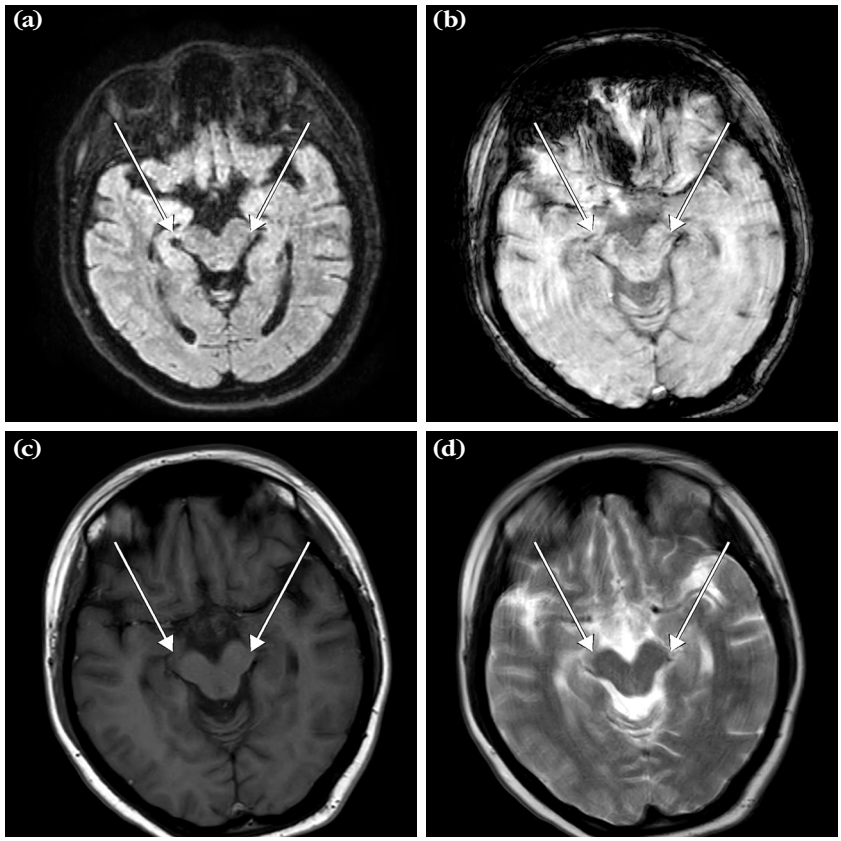

Figure 3. Apparent preservation of the substantia nigra on dedicated midbrain sections. Axial **(a)** fluid-attenuated inversion recovery, **(b)** susceptibility-weighted, **(c)** T1-weighted, and **(d)** T2-weighted images are shown. At the expected nigral locations (arrows), the T2-weighted and susceptibility-weighted images show no definite pathologic bilateral hypointensity or blooming, and the T1-weighted and fluid-attenuated inversion recovery images show no corresponding focal abnormality. This contrasts with the canonical mitochondrial membrane protein-associated neurodegeneration pattern of concomitant pallidal and nigral iron deposition. Subtle nigral iron below the sensitivity of conventional 1.5-T sequences cannot be excluded.

Genomics/Association for Molecular Pathology criteria supported likely pathogenicity (PM3, PM2_supporting, PP1, PP3, and PP4), replacing the report's legacy "pathogenic, Class 1" wording. PM3 and PP1 derive from affected recessive families reported with this allele, whereas segregation was not established in the present family.

The canonical MPAN pattern is iron accumulation in both globus pallidus and substantia nigra, often with an isointense-to-hyperintense medial medullary lamina between hypointense pallidal segments.[1,2] Hogarth et al.[2] found pallidal iron in 23/23 and nigral iron in 21/23 patients; none had a classic eye-of-the-tiger sign, while five had medial medullary lamina streaking. Thus, pallidal-predominant disease is uncommon but not unprecedented. Importantly, the same legacy c.194G>T, p.(Gly65Val) allele was associated with blooming in both globus pallidus and substantia nigra in the adolescent described by Yoganathan et al.[3] and with combined pallidal and nigral iron in the comparator case illustrated by Alavi et al.[4] A clinically similar 23-year-old female with onset at 10 years and an eye-of-the-tiger sign in MPAN was reported by Dehghan Manshadi et al.,[5] but patient-level midbrain susceptibility images and nigral status were not provided. Therefore, the combination of an eye-of-the-tiger-like pallidal pattern and no definite visually detectable nigral iron appears exceptional, and its occurrence with the same allele reported in pallidonigral cases broadens intragenotypic radiologic variability

TABLE 1
Comparative magnetic resonance imaging features of the present case, selected mitochondrial membrane protein-associated neurodegeneration reports, and major neurodegeneration-with-brain-iron-accumulation differentials

Report/disorder	Gene/inheritance	Globus pallidus	Substantia nigra	Additional imaging/context	Source
Present case	C19orf12; biallelic NM_031448.6:c.161G>T, p.(Gly54Val)	Symmetric T2 hypointensity and SWI blooming; central medial-lamina hyperintensity creates eye-of-the-tiger-like pallidal splitting	No definite bilateral T2 hypointensity or SWI blooming on dedicated 1.5-T sections; no focal T1/FLAIR correlate	Qualitative only; QSM/R2* and longitudinal imaging unavailable	This report
MPAN cohort	C19orf12; autosomal recessive	Iron in 23/23; medial medullary lamina streak in 5/23; classic eye-of-the-tiger sign in 0/23	Iron in 21/23	Demonstrates that pallidal-predominant disease occurs but is uncommon	Hogarth et al.[2]
Same-allele adolescent	C19orf12; legacy c.194G>T, p.(Gly65Val)	Pallidal hypointensity with medial-lamina hyperintensity; susceptibility blooming	Susceptibility blooming reported	Mild cerebellar atrophy	Yoganathan et al.[3]
Same-allele comparator	C19orf12; homozygous legacy p.(Gly65Val)	Iron deposition	Iron deposition	Extensive brain iron deposition illustrated	Alavi et al.[4]
Eye-of-the-tiger MPAN case	C19orf12; homozygous variant	Eye-of-the-tiger sign reported	Patient-level midbrain susceptibility image/status not shown or reported	Clinically similar 23-year-old woman; onset at 10 years	Dehghan Manshadi et al.[5]
Pantothenate kinase-associated neurodegeneration	PANK2; autosomal recessive	Typically globus pallidus; rounded central hyperintensity may form the classic eye-of-the-tiger sign	May be involved; usually less defining than pallidal pattern	Classic rounded central pallidal configuration	Lee et al.[1]
Beta-propeller protein-associated neurodegeneration	WDR45; X-linked dominant	Variable, often less than nigral involvement	Substantia nigra-predominant iron	T1 hyperintense halo around a central hypointense band in the substantia nigra	Lee et al.[1]
PLA2G6-associated neurodegeneration	PLA2G6; autosomal recessive	Variable pallidal iron	Variable nigral iron	Disproportionate cerebellar atrophy is a useful clue	Lee et al.[1]
Fatty acid hydroxylase-associated neurodegeneration	FA2H; autosomal recessive	Pallidal iron	Nigral iron may occur	White-matter disease, pontocerebellar atrophy, thin corpus callosum	Lee et al.[1]
Neuroferritinopathy	FTL; autosomal dominant	Widespread iron; pallidal cavitation may develop	Often involved within widespread distribution	Cortical pencil-lining and cystic basal-ganglia degeneration	Lee et al.[1]
Aceruloplasminemia	CP; autosomal recessive	Widespread iron	Widespread iron	Systemic iron phenotype and diabetes/retinal disease may support diagnosis	Lee et al.[1]

SWI, susceptibility-weighted imaging; FLAIR, fluid-attenuated inversion recovery; QSM, quantitative susceptibility mapping; MPAN, mitochondrial membrane protein-associated neurodegeneration. Data in each comparison row are cited in the Source column. "Not shown or reported" is not equivalent to radiologic absence.

without supporting a claim of absolute or first-ever nigral sparing. The same-allele contrasts indicate that p.(Gly54Val) does not impose a fixed regional iron-distribution phenotype. The principal contribution of our case is therefore diagnostic: visually inapparent nigral involvement on dedicated conventional sequences should not exclude MPAN, while an eye-like pallidal pattern should not be attributed to pantothenate kinase-associated neurodegeneration without molecular confirmation. Dedicated midbrain-level susceptibility review remains essential.

The medial-lamina-based configuration represents an eye-of-the-tiger mimic within genetically confirmed MPAN rather than the classic rounded central pallidal hyperintensity of PANK2-related pantothenate kinase-associated neurodegeneration. Other useful distinctions are substantia nigra-predominant iron deposition with a T1 halo in beta-propeller protein-associated neurodegeneration, disproportionate cerebellar atrophy in PLA2G6-associated neurodegeneration, white-matter disease with pontocerebellar atrophy and a thin corpus callosum in fatty acid hydroxylase-associated neurodegeneration, and widespread iron with cavitation or cortical pencil-lining in neuroferritinopathy (Table 1).[1] The biallelic genotype and clinically unaffected parents favor autosomal recessive inheritance. Although monoallelic C19orf12 variants can cause dominant disease, the unverified cousins cannot be used for segregation. If they share the same recessive disorder, their unrelated mothers would also need to contribute a disease-associated allele; phenocopies or inaccurate family reporting remain plausible. Therefore, parental testing, copy-number/phase assessment, and clinical-genetic evaluation of the cousins are important limitations.

Author Contributions: A.K.: Idea/concept, design, data collection and/or processing, analysis and/or interpretation, literature review, writing the article, and materials; İ.Ş.K.: Control/supervision and critical review.

Conflict of Interest: The authors declared no conflicts of interest with respect to the authorship and/or publication of this article.

Funding: The authors received no financial support for the research and/or authorship of this article.

AI Disclosure: The authors declare that artificial intelligence (AI) tools were not used, or were used solely for language editing, and had no role in data analysis, interpretation, or the formulation of conclusions. All scientific content, data interpretation, and conclusions are the sole responsibility of the authors. The authors further confirm that AI tools were not used to generate, fabricate, or 'hallucinate' references, and that all references have been carefully verified for accuracy.

REFERENCES

1. Lee JH, Yun JY, Gregory A, Hogarth P, Hayflick SJ. Brain MRI pattern recognition in neurodegeneration with brain iron accumulation. Front Neurol 2020;11:1024. doi: 10.3389/fneur.2020.01024.
2. Hogarth P, Gregory A, Kruer MC, Sanford L, Wagoner W, Natowicz MR, et al. New NBIA subtype: Genetic, clinical, pathologic, and radiographic features of MPAN. Neurology 2013;80:268-75. doi: 10.1212/WNL.0b013e31827e07be.
3. Yoganathan S, Sudhakar SV, Thomas M, Dutta AK, Danda S. "Eye of tiger sign" mimic in an adolescent boy with mitochondrial Membrane Protein Associated Neurodegeneration (MPAN). Brain Dev 2016;38:516-9. doi: 10.1016/j.braindev.2015.10.017.
4. Alavi A, Mokhtari M, Hajati R, Davarzani A, Fasano A, Lang AE, et al. Late-onset mitochondrial membrane protein-associated neurodegeneration with extensive brain iron deposition. Mov Disord Clin Pract 2019;7:120-1. doi: 10.1002/mdc3.12868.
5. Dehghan Manshadi M, Rohani M, Rezaei A, Aryani O. A case of MPAN with "Eye of the Tiger Sign," mimicking PKAN. Mov Disord Clin Pract 2022;9:693-5. doi: 10.1002/mdc3.13493.