Turkish Journal of Neurology

Turk J Neurol 2026;32(4):314-317
Doi: 10.55697/tnd.2026.728

LETTER TO THE EDITOR

Isolated anti-Zic4 positivity in a reversible cognitive and behavioral syndrome without malignancy: A diagnostic pitfall

Okan Sokmen[1], Gül Yalçın Çakmaklı[2], Serap Saygi[2]

[1]Department of Neurology, Atatürk Sanatorium Training and Research Hospital, Ankara, Türkiye
[2]Department of Neurology, Hacettepe University Faculty of Medicine, Ankara, Türkiye

Neuronal antibody positivity is increasingly encountered in patients presenting with cognitive and behavioral symptoms, although its clinical significance is not always clear. Anti-Zic4 antibodies, which target intracellular antigens, are typically considered markers of paraneoplastic neurological syndromes (PNSs) rather than directly pathogenic antibodies.[1] Isolated cognitive and behavioral presentations without detectable malignancy are rarely reported.[2] We report a patient with isolated anti-Zic4 positivity presenting with a reversible cognitive syndrome, whose malignancy screening remained negative at baseline and during six years of follow-up. The marked clinical improvement in the absence of immunotherapy highlights the potential for misinterpretation of neuronal antibodies in neuropsychiatric presentations.

A 63-year-old male was admitted with a two-month history of progressive cognitive impairment and behavioral changes, characterized by forgetfulness, anxiety, sleep disturbance, and occasional disorientation, leading to functional decline. The patient had vascular risk factors, including chronic smoking. There were no focal neurological deficits or systemic features suggestive of an underlying malignancy. A written informed consent was obtained from the patient.

Neuropsychological assessment revealed impaired global cognition (Mini-Mental State Examination score, 19), with prominent memory deficits and executive dysfunction, accompanied by severe depressive symptoms (Geriatric Depression Scale score, 23). Brain magnetic resonance imaging showed bilateral white matter hyperintensities and mild frontal atrophy, without findings suggestive of limbic encephalitis (Figure 1). Electroencephalography was normal. Cerebrospinal fluid analysis demonstrated isolated protein elevation (67 mg/dL; reference range, 15-40 mg/dL) without pleocytosis or intrathecal immunoglobuline (Ig)G synthesis.

Serum testing at an external reference laboratory revealed isolated anti-Zic4 antibody positivity (1+) by immunoblot, while an extended neuronal antibody panel was otherwise negative. Extensive malignancy screening, including thoracoabdominal computed tomography, scrotal ultrasonography, and whole-body positron emission tomography/computed tomography, revealed no evidence of malignancy. Immunotherapy was not initiated, as clinical, radiological, and laboratory findings did not support an autoimmune process. The patient received low-dose antipsychotic treatment for behavioral symptoms, with progressive clinical improvement. At follow-up, neuropsychological testing demonstrated marked improvement, with normalization of global cognition (Mini-Mental State Examination score, 25) and memory

Correspondence: Okan Sokmen, MD. Atatürk Sanatoryum Eğitim ve Araştırma Hastanesi, Nöroloji Kliniği, 06290 Keçiören, Ankara, Türkiye
E-mail: drokansokmen@gmail.com
Received: May 22, 2026 **Accepted:** July 09, 2026 **Published online:** August 27, 2026
Cite this article as: Sokmen O, Yalçın Çakmaklı G, Saygi S. Isolated anti-Zic4 positivity in a reversible cognitive and behavioral syndrome without malignancy: A diagnostic pitfall. Turk J Neurol 2026;32(4):314-317. doi: 10.55697/tnd.2026.728

© Copyright 2026 by the Turkish Neurological Society. This work is licensed under the Creative Commons Attribution-NonCommercial-NoDerivatives 4.0 International License (CC BY-NC-ND 4.0). To view a copy of this license, visit https://creativecommons.org/licenses/by-nc-nd/4.0/

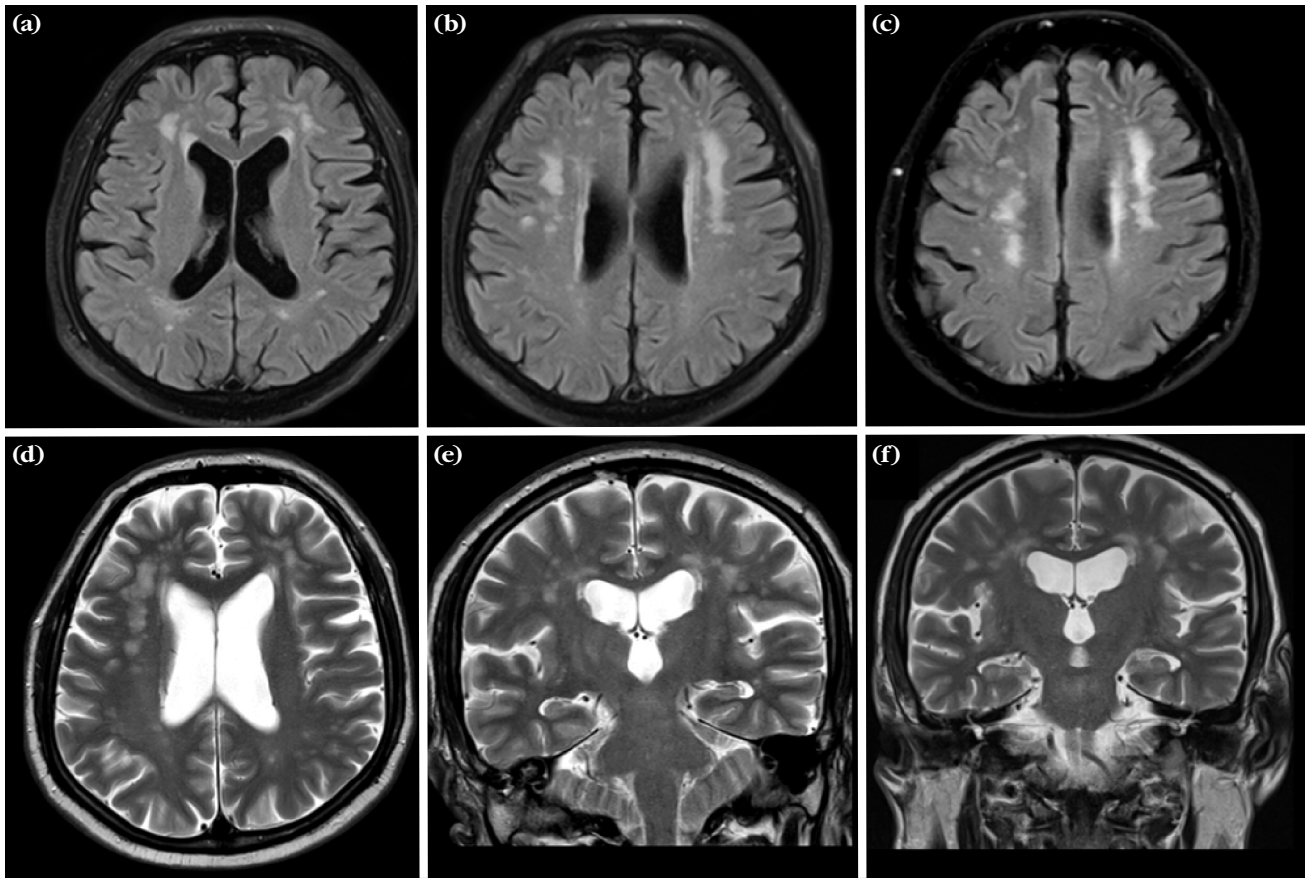

Figure 1. Brain magnetic resonance imaging demonstrating bilateral nonspecific white matter hyperintensities and mild frontal atrophy without mesial temporal abnormalities suggestive of limbic encephalitis. **(a-c)** Axial FLAIR images show scattered periventricular and subcortical white matter hyperintensities. **(d-f)** Axial and coronal T2-weighted images demonstrate mild diffuse cerebral and frontal-predominant atrophy.

TABLE 1
Comparison of neuropsychological test performance at baseline and follow-up

Domain	Test	Baseline	Follow-up (18 months)
Global cognition	MMSE	19	25
Memory	Enhanced Cued Recall	22	48
Executive functions	Trail making test B	Could not complete	Completed
Verbal fluency	Letter fluency	5	8
Verbal fluency	Semantic fluency	13	17
Attention	Digit span	7	8
Sequencing	Months backward	Could not complete	Completed
Mood	GDS score	23	6

MMSE, mini-mental state examination; GDS, Geriatric Depression Scale.

performance, as well as a significant reduction in depressive symptoms (Geriatric Depression Scale score, 6) (Table 1). During six years of follow-up, no malignancy emerged, and the patient remained clinically stable.

Anti-Zic4 antibodies are most commonly associated with PNSs, particularly small-cell lung carcinoma, and are typically linked to cerebellar or other neurological manifestations.[1,3] As antibodies against intracellular antigens, they are

generally considered markers of T-cell–mediated immune responses rather than directly pathogenic antibodies.[4,5]

In our patient, several findings argued against autoimmune encephalitis. Neuroimaging revealed only nonspecific white matter changes without features suggestive of limbic encephalitis, cerebrospinal fluid analysis showed no evidence of intrathecal inflammation, and no additional neuronal antibodies were detected. The white matter hyperintensities were considered more consistent with chronic small vessel ischemic changes related to the patient's vascular risk factors than with an inflammatory process. Follow-up magnetic resonance imaging demonstrated radiological stability without progression of these lesions. Moreover, the clinical presentation did not fulfill established diagnostic criteria for autoimmune encephalitis.[4] Likewise, a diagnosis of PNS was not supported in our patient. Recent PNS criteria emphasize the combined assessment of clinical phenotype, antibody risk category, and associated malignancy, rather than antibody positivity alone.[6] Anti-Zic4 is not currently classified as a high-risk onconeural antibody, and our patient lacked both a characteristic PNS phenotype and an associated malignancy despite extensive baseline screening and six years of follow-up. Therefore, the isolated antibody finding was considered of limited clinical significance.[6]

An alternative and more plausible explanation for the clinical picture is depression-related cognitive impairment. Severe depressive symptoms were present at baseline, and both mood and cognitive functions improved markedly during follow-up without immunotherapy. This pattern is consistent with reversible depression-related cognitive impairment, sometimes referred to as pseudodementia, which may mimic neurodegenerative or autoimmune conditions.[5]

Importantly, the detection of anti-Zic4 antibodies in this case may represent an epiphenomenon rather than a causative factor, particularly in the absence of a compatible clinical syndrome. In our patient, anti-Zic4 positivity occurred in the absence of a compatible neurological syndrome, associated malignancy, or supportive ancillary findings. Incidental neuronal antibody positivity may occasionally be encountered in patients without definite autoimmune encephalitis. With the increasing use of neuronal antibody testing in patients with cognitive and psychiatric symptoms, there is a growing risk of overinterpretation. In such cases, reliance on antibody positivity without adequate clinical correlation may lead to misdiagnosis and unnecessary immunotherapy.[2]

In conclusion, this case highlights the importance of interpreting neuronal antibody results within the broader clinical, radiological, and laboratory context. Reliance on antibody positivity alone may lead to unnecessary immunotherapy, increased healthcare costs, and potential treatment-related adverse effects. In cases with spontaneous clinical improvement, such interventions may also result in incorrect attribution of recovery to immunotherapy. Neuronal antibody positivity, particularly against intracellular antigens, should not replace clinical judgment. Antibody results should always be interpreted within the appropriate clinical context to avoid diagnostic errors and unnecessary immunotherapy.

Author Contributions: O.S., G.Y.Ç., S.S.: Concept and design; G.Y.Ç., S.S.: Supervision; O.S.: Surgical and medical practices, data collection and/or processing, analysis and/or interpretation, literature review, and writing.

Conflict of Interest: The authors declared no conflicts of interest with respect to the authorship and/or publication of this article.

Funding: The authors received no financial support for the research and/or authorship of this article.

AI Disclosure: The authors declare that artificial intelligence (AI) tools were not used, or were used solely for language editing, and had no role in data analysis, interpretation, or the formulation of conclusions. All scientific content, data interpretation, and conclusions are the sole responsibility of the authors. The authors further confirm that AI tools were not used to generate, fabricate, or 'hallucinate' references, and that all references have been carefully verified for accuracy.

REFERENCES

1. Bataller L, Wade DF, Graus F, Stacey HD, Rosenfeld MR, Dalmau J. Antibodies to Zic4 in paraneoplastic neurologic disorders and small-cell lung cancer. Neurology 2004;62:778-82. doi: 10.1212/01.wnl.0000113749.77217.01.
2. Etemadifar M, Aghababaei A, Nouri H, Kargaran PK, Mohammadi S, Salari M. Autoimmune encephalitis: The first observational study from Iran. Neurol Sci 2022;43:1239-48. doi: 10.1007/s10072-021-05400-1.
3. Akçadağ T, Korkmaz M, Ünal Y, et al. A rare case of paraneoplastic syndrome. Turk J Neurol 2023;29:77-8. doi: 10.4274/tnd.2022.95595.
4. Graus F, Titulaer MJ, Balu R, Benseler S, Bien CG, Cellucci T, et al. A clinical approach to diagnosis of autoimmune encephalitis. Lancet Neurol 2016;15:391-404. doi: 10.1016/S1474-4422(15)00401-9.

5. Semkovska M, Quinlivan L, O'Grady T, Johnson R, Collins A, O'Connor J, et al. Cognitive function following a major depressive episode: A systematic review and meta-analysis. Lancet Psychiatry 2019;6:851-61. doi: 10.1016/S2215-0366(19)30291-3.

6. Graus F, Vogrig A, Muñiz-Castrillo S, Antoine JG, Desestret V, Dubey D, et al. Updated diagnostic criteria for paraneoplastic neurologic syndromes. Neurol Neuroimmunol Neuroinflamm 2021;8:e1014. doi: 10.1212/NXI.0000000000001014.