

Neuroimaging in Epilepsy

Christian Vollmar, Soheyl Noachtar

University of Munich Department of Neurology MUNICH, GERMANY

ÖZET

Epilepside Nörogörüntüleme

Bu değerlendirmede epilepside nörogörüntüleme konusundaki mevcut yaklaşım ele alınmaktadır. Epilepsi hastalarının operasyon öncesi nörogörüntüleme bulguları sunulmakta ve belli manyetik rezonans görüntüleme (MRG) protokolleri için önerilerde bulunmaktadır. Epilepsilere ait işlevsel MRG, MR spektroskopisi, ve difüzyon tansör görüntülemeyi kapsayan tipik MRG bulguları yeniden gözden geçirilmektedir. İşlem sonrası görüntüde yeni gelişmeler ile birlikte pozitron-emisyon tomografisi ve tek foton emisyon bilgisayarlı tomografi gibi işlevsel görüntüleme yöntemlerinin klinik kullanımı özetlenmektedir.

ABSTRACT

This review covers the current approach to neuroimaging in epilepsy. Some conceptual considerations for the interpretation of neuroimaging findings are also discussed. An algorithm for neuroimaging in the presurgical evaluation of epilepsy patients is presented, and recommendations are given for specific magnetic resonance imaging (MRI) protocols. The typical findings on MRI, including functional MRI, MR spectroscopy, and diffusion tensor imaging, in the epilepsies are reviewed. The clinical use of functional imaging methods such as positron-emission tomography and single photon emission computed tomography is summarized, including current developments of image post-processing.

Yazışma Adresi / Address for Correspondence: PD Dr. S. Noachtar
Department of Neurology University of Munich Marchioninstr. 15, 81377 Munich,
Germany
Phone: +49-89-70 95 2685 / -3691 Fax: +49-89-70 95 3677
noa@med.uni-muenchen.de

Dergiyeye Ulaşma Tarihi/Received: 20.04.2004

Kesin Kabul Tarihi/Accepted: 20.04.2004

INTRODUCTION

Epilepsy is one of the most common neurological disorders. The majority of epilepsy patients who present with a first epileptic seizure undergo neuroimaging procedures. There are two settings in which neuroimaging plays an essential role:(1) in patients with the first seizure and (2) in patients with chronic medically refractory focal epilepsies. In the acute setting of the first seizure, neuroimaging is primarily performed to detect the underlying causes that require immediate treatment, e.g., intracranial hemorrhage, encephalitis, infarction, or mass lesions such as tumors. CT scans are typically the first modality used, since they are more readily available in emergency situations than MRI and usually sufficient to identify the pathologies mentioned above. However, CT is likely to miss several epileptogenic lesions such as mesial temporal sclerosis, cavernomas, and focal cortical dysplasia, which are common in patients with chronic epilepsies. The imaging methods

used in specific settings depend on the clinical yield and availability of the different methods. For example, the evaluation of patients with new onset generalized tonic-clonic seizures without focal onset may be limited to a standard MRI or CT scan to primarily exclude lesions. In contrast, extensive imaging studies may be performed in patients with medically intractable focal epilepsies, in whom epilepsy surgery is being considered, to identify the epileptogenic zone and to determine its boundaries (Noachtar, Winkler et al. 2003). Each imaging modality visualizes different aspects of the epileptogenic pathophysiology (Lüders and Awad 1992), and the individual results are either confirmatory or complementary. In the following we first discuss some conceptual considerations, which are important for the interpretation of the different diagnostic techniques (EEG, MRI, PET, SPECT, EEG-video monitoring) (Figure 1). Then we deal in detail with the different neuroimaging methods used in patients with epilepsy.

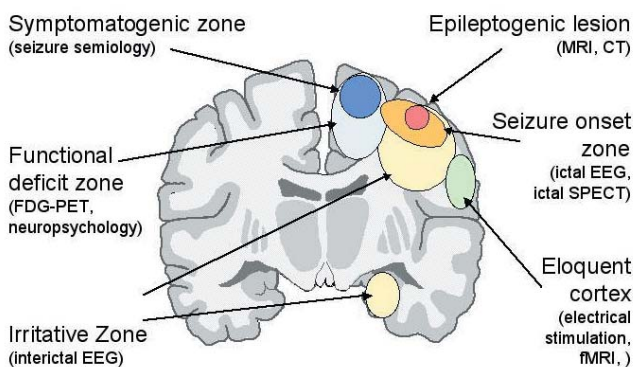


Figure 1. Conceptual considerations
This figure illustrates the topographic relation of the epileptogenic lesion identified by MRI with the results of other localizing diagnostic methods such as EEG-video monitoring, PET, SPECT, and neuropsychological testing (see text). There is a close relationship between these areas, which may also include remote regions, as shown for the irritative zone.

Conceptual Considerations

Epileptogenic lesion

Structural lesions causing epilepsies are called epileptogenic lesions (Figure 1). The best method to visualize them is high resolution MRI (Kuzniecky and Knowlton 2002). Typically the lesion itself, e.g., a tumor, is not the generator of the epileptic activity, but instead the effect it has on adjacent neurons (Rosenow and Lüders 2001). It is important to keep in mind that a lesion identified by imaging studies does not necessarily reflect the etiology of a given epilepsy syndrome. For instance, a patient with

juvenile myoclonic epilepsy, a common idiopathic generalized epilepsy syndrome, may have a temporal cavernoma, but this does not represent an epileptogenic lesion, unless it is proven that in addition to the generalized seizures, other seizures arise from the temporal cavernoma. Therefore, results of imaging studies always have to be interpreted in the light of the epilepsy syndrome that a given patient has.

Irritative zone

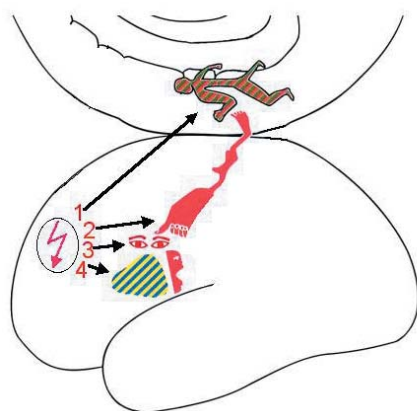
The irritative zone is defined as the area generating interictal epileptiform discharges which are recorded on EEG (Figure 1). This region is usually more extensive than the epileptogenic lesion. Considerable experience with surface EEG has established that patients with mesial temporal lobe epilepsy, for example, also exhibit temporal epileptiform discharges. Localization of the irritative zone may be improved by using source analysis tools to evaluate EEG and MEG data (Stefan, Hummel et al. 2003) or spike-triggered fMRI to localize a circumscribed BOLD response as a result of the spike activity (Jäger, Werhahn et al. 2002).

Seizure onset zone

The seizure onset zone is the cortical area from which the patient's habitual seizures originate (Figure 1). Since the epileptic discharge will spread outside this zone in clinical seizures, it is usually difficult to identify it precisely. Even EEG recordings with invasive electrodes may have difficulties to define the seizure onset zone and delineate it from early propagation to adjacent regions. Ictal SPECT shows a regional hyperperfusion in the region of epileptic seizure activity, and thus is able to provide localizing information. However, rapid seizure spread may influence the results, particularly in extratemporal epilepsies (Noachtar, Arnold et al. 1998). Therefore, ictal perfusion SPECT will most likely show a combination of the seizure onset zone and propagation of epileptic activity to other regions, depending on the time of tracer injection after seizure onset. The seizure onset zone is almost always included in the irritative zone.

Symptomatogenic zone

Epileptic activity will only lead to clinical signs and symptoms if symptomatogenic cortex is involved in the epileptic activity (Figure 1). Extensive invasive EEG evaluations have shown that there are cortical regions in which epileptic activation is not associated with any clinical symptomatology. In such cases only the spread of epileptic activity to



1. Bilateral tonic seizure
2. Right hand clonic seizure
3. Right versive seizure
4. Aphasic seizure

Figure 2. Seizure spread

The symptomatology of a seizure arising from the left frontopolar region depends on the seizure spread pattern: (1) spread to the supplementary sensorimotor area leads to a bilateral asymmetric tonic seizure, (2) spread to the primary somatomotor hand area results in a clonic seizure of the right hand, (3) spread to the frontal eye field causes right versive seizure, and (4) spread to Wernicke's area results in an aphasic seizure.

symptomotogenic areas will lead to ictal clinical symptoms (Figure 2). For example, a seizure starting in the frontopolar region will lead to contralateral version of the eyes and head when the epileptic activity has spread to the frontal eye field (Figure 2). The initial clinical symptomatology has high localizing value, because it is usually close to the seizure onset zone (Lüders and Awad 1992).

Functional deficit zone

The functional deficit zone defines the areas of cortical dysfunction in the interictal state (Figure 1). The underlying cause of the dysfunction can be the effect of an epileptogenic lesion itself or of secondary reactions like edema. Also a high frequency of seizures or interictal discharges is held responsible for causing functional deficits (Lüders and Awad 1992; Engel 2002). These deficits can usually be identified by neurological or neuropsychological testing. In some patients the functional deficit zone may show a close topographic relationship to the seizure onset zone or the irritative zone, such as memory deficits in patients with temporal lobe epilepsy. However, due to remote effects of epileptic brain activity the functional deficit zone is typically more extensive than the seizure onset zone (Arnold, Schlaug et al. 1996). This is consistent with the extended areas revealed in neuroimaging which show reduced glucose metabolism in FDG-PET scans and reduced interictal perfusion in SPECT.

Epileptogenic zone

The epileptogenic zone is defined as the cortical area, whose complete removal is necessary and sufficient to achieve seizure freedom. However, the epileptogenic zone is basically a theoretical concept that is not directly accessible to diagnostic procedures. Of course, the seizure onset zone is an essential part of the epileptogenic zone, but there is evidence that additional areas have to be resected to ensure seizure freedom. For instance, parts of the irritative zone seem capable of assuming the pacemaker function and of generating seizures after removal of the initial seizure onset zone. To what extent parts of the irritative zone should be resected for good post-surgical outcome is still an open question.

Algorithm for presurgical evaluation of medically refractory focal epilepsies

Most patients with medically refractory focal epilepsies, in whom epilepsy surgery is being considered, do not need invasive evaluation (Sperling, O'Connor et al. 1992; Winkler, Herzog et al. 1999). In some, however, the identification of the epileptogenic zone requires invasive EEG recordings, typically with subdural or depth electrodes. The implantation of invasive electrodes is associated with complications (Van Buren 1987) that are only justified if a clear hypothesis about the epileptogenic zone has been derived from non-invasive studies and if the presumed epileptogenic zone is potentially resectable (Noachtar, Winkler et al. 2003). MRI

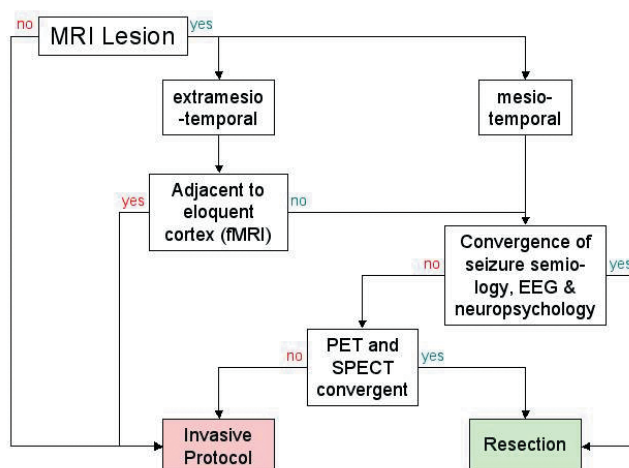


Figure 3. Presurgical evaluation of epilepsy

This algorithm summarizes the presurgical evaluation of epilepsy patients depending on the results of neuroimaging, EEG-video monitoring, and neuropsychological testing. The presence or absence of a structural lesion in the MRI is crucial. It is currently recommended to proceed to resective epilepsy surgery without prior invasive EEG recording only in cases where well-defined MRI lesions in resectable areas (typically mesial temporal lobe) are not adjacent to eloquent cortex.

plays a key role in the presurgical evaluation, because it provides essential localizing information. The algorithm of the University of Munich Epilepsy Center is summarized in Figure 3 (Noachtar, Winkler et al. 2003).

If MRI reveals evidence of mesial temporal sclerosis, consistent with electroclinical and neuropsychological data indicating unilateral mesial temporal lobe epilepsy, non-invasive studies will be sufficient to define the epileptogenic zone and proceed to partial anterior and mesial temporal lobectomy. This is the result of decades of invasive EEG evaluations (Risinger, Engel et al. 1989). If the results of clinical evaluation and EEG-video monitoring are contradictory, functional imaging techniques such as PET and SPECT may add localizing information. If PET or SPECT reveal contralateral, bilateral, or extratemporal abnormalities, invasive EEG recordings are recommended.

Invasive EEG recordings are required in patients with extramesiotemporal lesions identified by MRI, if the epileptogenic zone is adjacent to eloquent cortex or if non-invasive methods reveal conflicting results, leaving doubts as to the localization or exact extent of the epileptogenic zone (Noachtar, Winkler et al. 2003). However, a testable hypothesis has to be the basis of further invasive evaluation.

Imaging Modalities

Structural magnetic resonance imaging (MRI)

MRI frequently identifies structural pathology in the epileptic brain (Duncan 1997). The percentage of patients with lesions identified by MRI continues to increase because of the improvements in image acquisition and data processing made in recent years (Von Oertzen, Urbach et al. 2002). Thus, whenever a neuroimaging study is reported as 'normal' and a given epilepsy syndrome is classified as 'cryptogenic', it is important to consider the specific MR techniques used. It is likely that state-of-the-art neuroimaging techniques appropriate for a given clinical question will reveal new findings that were missed by typical, standard MR protocols (Duncan 1997). A recent study compared the sensitivity of "standard MRI" examinations rated by general radiologists and neuroradiological experts in epilepsy with the results of experts reading epilepsy-specific MRI scans. The most striking difference was found for the detection of mesial temporal sclerosis: non-experts reading standard MRI detected mesial temporal sclerosis in only 7% of the 123 patients with refractory focal epilepsies. Reevaluation of standard MRI by experts improved the yield to 18%, and experts reading specific MRI scans revealed mesial temporal sclerosis in 45%. The discrepancy was similar in extratemporal lesions. In total, specific MRI

read by experts detected lesions in 85% of the patients with prior negative standard MRI (Von Oertzen, Urbach et al. 2002).

Defining a state-of-the-art protocol for structural MRI has to keep in mind that technical improvements may soon overtake recommendations. The following protocol is currently used at the University of Munich Epilepsy Center:

- Each MRI includes transverse T1, T2, and FLAIR (fluid-attenuated inversion recovery) images with a slice thickness of not more than 5 mm. FLAIR images, also known as 'dark fluid' images, are T2 images with suppressed signal of the cerebrospinal fluid.
- For temporal lobe epilepsy, additional coronal 3-mm T1, T2, and FLAIR images perpendicular to the long axis of the hippocampus are acquired. Planning of these slices is improved by using an extended scout-scan, which provides several sagittal planes, in which the hippocampus can be identified. The use of T1-weighted inversion recovery sequences provides a better contrast between gray and white matter and improves the analysis of the internal architecture of hippocampal formations. High-resolution T1 images with a slice thickness of 1 mm are only needed for volumetric studies and can be omitted for visual analysis. FLAIR images have a higher sensitivity for sclerosis than T2-weighted images (Bergin, Fish et al. 1995; Jack, Rydberg et al. 1996).
- The acquisition of a high-resolution T1-weighted gradient echo sequence with an in-plane resolution and slice thickness of 1 mm is recommended for extratemporal lobe epilepsy. This allows reconstruction of arbitrary planes in the data set without significant loss of image quality and aids the detection of subtle focal cortical dysplasia. Additional Inversion Recovery (IR) sequences with 3-mm-slice thickness can further improve the detection of cortical dysplasia or heterotopia due to the improved gray and white matter contrast. Increasing the resolution of FLAIR images enhances the detection of tumors and post-traumatic scars (Wieshmann, Barker et al. 1998).
- The use of contrast medium is only necessary if inflammations or tumors are suspected.

Temporal lobe epilepsy

The most common structural abnormality to be identified by MRI in temporal lobe epilepsy is mesial temporal sclerosis (MTS). It is followed by tumors and other etiologies such as infarcts, vascular malformations, or inflammatory lesions (Jensen and Klinken 1976; Kuzniecky, de la Sayette et al. 1987). The most frequent form of MTS is restricted to only the hippocampal formation. In a series of 168 resected

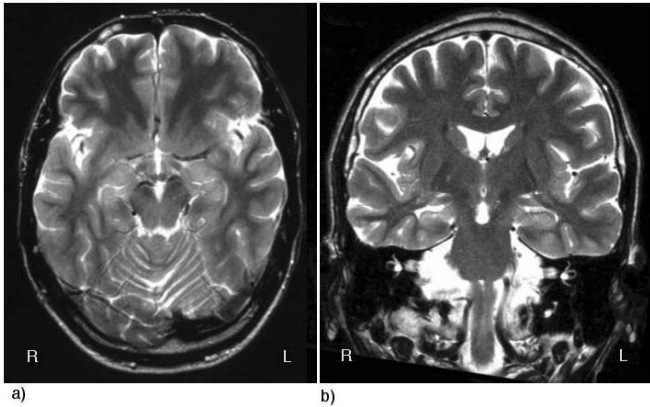


Figure 4. Adequate MRI technique

The left image (a) shows a transverse T2-weighted image with 6-mm-slice thickness. There is no obvious difference between the two temporal lobes. The right image (b) shows a coronal 3-mm slice perpendicular to the long axis of the hippocampus. It shows a volume reduction in the anterior part of the right hippocampus, consistent with seizures arising from the right mesial temporal region as documented by EEG.

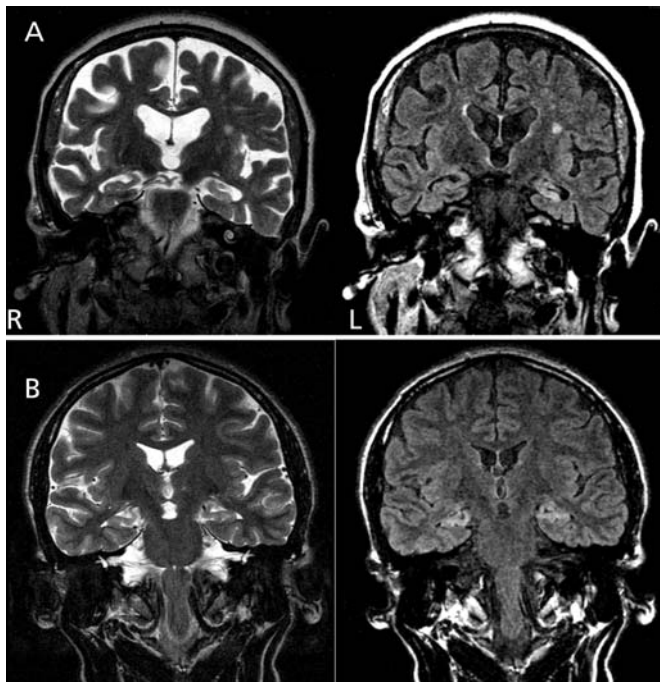


Figure 5. FLAIR imaging in mesial temporal sclerosis

The T2-weighted and FLAIR images (upper row; Figure 5a) show increased signal in the left hippocampus of a patient with left mesial temporal sclerosis (MTS). The signal increase is more readily detected in the FLAIR image (upper right) than in the T2 image. The hippocampal volume in the T2 image (upper left) is not asymmetric. Thus, the signal increase in FLAIR image is more sensitive for the detection of MTS than the volume assessment of the mesial temporal structures in this case.

The lower row (b) shows images of a patient with bilateral mesial temporal epilepsy. T2 images (lower left) show symmetric hippocampal volume and configuration. The corresponding FLAIR image (lower right) reveals regional signal increase in both hippocampi, confirming bilateral MTS.

specimens only 12% showed additional sclerosis in the amygdala (Lee, Gao et al. 1998). MRI was reported to have a sensitivity of 93% and specificity of 83% for the detection of mesial pathologies (Lee, Gao et al. 1998), a finding that is consistent with other studies (Duncan 1997). Coronal images show a loss of hippocampal volume in MTS. Figure 4 shows an example of right MTS. While the axial image (Figure 4a) does not indicate this loss in volume, it is clearly seen in the coronal section (Figure 4b). MTS is also associated with increased signal intensity in T2 and FLAIR images. The sensitivity of FLAIR images is superior to T2, and signal increase in FLAIR images usually precedes perceptible volume loss of the hippocampal formation (Figure 5a) (Jack, Rydberg et al. 1996). Ipsilateral MTS is a favorable prognostic factor for patients being considered for resective temporal lobe epilepsy surgery (Berkovic, Andermann et al. 1991; Garcia-Flores 1994). Contralateral MTS is present to a minor extent in most patients with MTS (Margerison and Corsellis 1966). However, more severe bilateral MTS associated with bilateral interictal epileptiform discharges is a poor prognostic factor for epilepsy surgery (Schulz, Luders et al. 2000). (Figure 5b) shows coronal T2-weighted images of a patient with bilateral mesial temporal lobe epilepsy documented by ictal EEG-video recordings. The hippocampal formation is atrophic bilaterally. The morphology of the internal architecture at the limits of spatial resolution of the images is not disturbed. However, FLAIR images show increased signal in both hippocampal formations (Figure 5b); this indicates bilateral MTS. Severe cognitive deficits are commonly observed in patients with bilateral MTS and seizures arising from either temporal lobe. These patients will most likely not benefit from temporal lobe epilepsy surgery and will experience a further decline of their cognitive performance. Thus, side-to-side comparison of hippocampal volume to detect asymmetry is not adequate to identify the bilateral pathology in these patients. Comparison of the hippocampal volume to that of normal controls is required, and this has to be age adjusted (Pfluger, Weil et al. 1999).

Hippocampal volumetry was reported to be superior to visual analysis of MTS (Rogachski, Mazer et al. 1998). This observation was not supported by others, who found that visual analysis was equal if not superior to volumetry (Cheon, Chang et al. 1998; Rogachski, Mazer et al. 1998). A major drawback of volumetry is that it requires long processing time and is not standardized.

MTS may coexist with additional pathology in temporal or extratemporal regions in some patients (dual pathology).

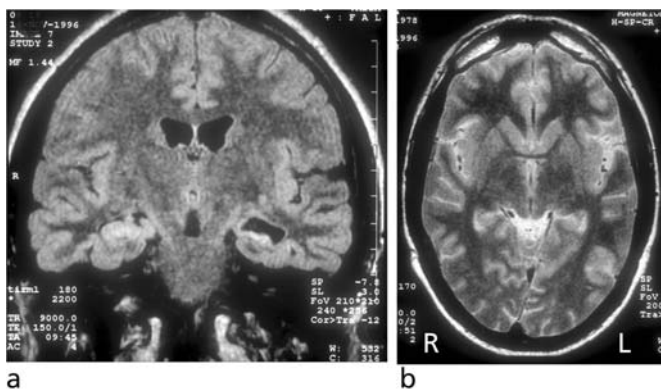


Figure 6. Dual pathology

Fig. 6a shows a coronal FLAIR image with severe left mesial temporal sclerosis. However, the axial T2 image (b) shows additional focal cortical dysplasia in the left parietal lobe (arrow).

Dual pathology with lesions such as neocortical temporal tumors, cavernomas, infarctions, or inflammatory lesions were found in 9% (Lee, Gao et al. 1998) to 30% (Levesque, Nakasato et al. 1991) of patients with MTS. Figure 6a shows an example of left MTS. Careful analysis reveals additional focal cortical dysplasia in the left parietal lobe (Figure 6b, arrow). The relative contribution of either lesion to the epileptogenicity must be meticulously investigated in patients with dual pathology.

Extratemporal lobe epilepsy

Common etiologies in extratemporal epilepsies include tumors, post-traumatic lesions, followed by migrational disorders like cortical dysplasia and rare vascular malformations or infectious sequelae (Robitaille, Rasmussen et al. 1992; Duncan 1997). The percentage of the pathologies reported varies between studies, depending on the patient populations. Figure 7 shows examples of bilateral band heterotopia (Figure 7a-b) and a periventricular small heterotopia in the left frontal white matter (Figure

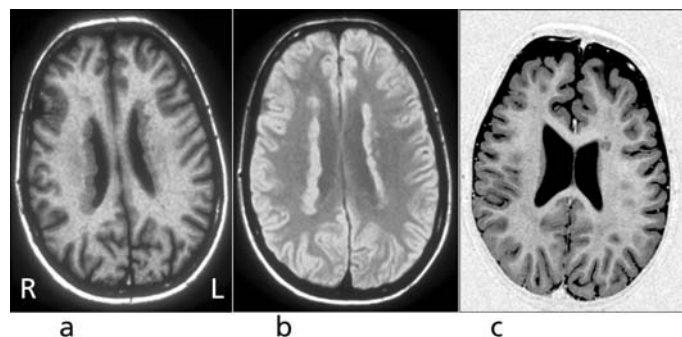


Figure 7. MRI in extratemporal lobe epilepsies

The two left images show a T1- (a) and proton-density (b) weighted image of a patient with bilateral periventricular band heterotopia. The right image (c) shows a T1-weighted inversion recovery (IR) image of a small nodular periventricular heterotopia in the left frontal white matter. Note the high contrast between gray and white matter with this technique.

7c). The results of epilepsy surgery in the so-called double cortex syndrome are poor (Bernasconi, Martinez et al. 2001). The results of resective epilepsy surgery in MRI-negative patients with extratemporal epilepsies have not been as good as in MRI-positive patients. However, recent studies show favorable surgical outcome in selected patients with negative MRI (Siegel, Jobst et al. 2001). Patient selection seems to be crucial. The extratemporal resections are not as standardized as in temporal lobe epilepsies, and the identification of the epileptogenic zone and its delineation from eloquent cortex are more complex. Invasive evaluations in MRI-negative patients have to rely on electroclinical and imaging data such as PET and SPECT to guide invasive evaluation in these patients (Noachtar, Winkler et al. 2003).

Temporary changes in MRI related to seizures

A generalized tonic clonic seizure (Kim, Chung et al. 2001) or status epilepticus can cause secondary transient alterations in MRI such as cytotoxic and vasogenic edema or contrast enhancement (Lansberg, O'Brien et al. 1999; Diehl, Najm et al. 2001). Similar transient abnormalities have been described in mitochondriopathy secondary to impaired regional metabolism (Tuxhorn, Holthausen et al. 1994). Figure 8 shows FLAIR images acquired after status epilepticus which reveal hyperintensity in the right superior

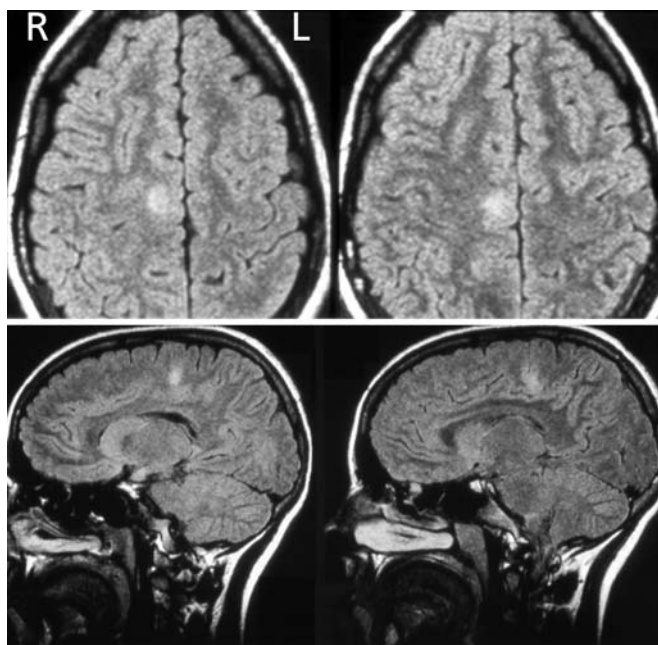


Figure 8. Transient imaging findings after seizures

These images were acquired after status epilepticus in a young female with normal structural MRI. FLAIR images show edema in the mesial portion of the right superior frontal gyrus, a transient change induced by focal epileptic activity.

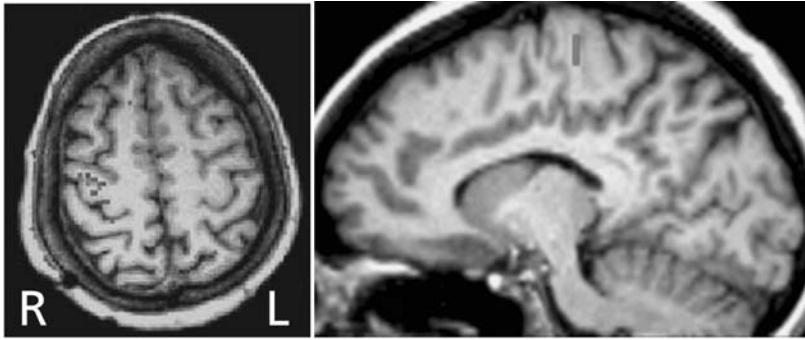


Figure 9. Functional MRI

fMRI identifies increased regional perfusion in the hand motor area in the right precentral gyrus during a left-handed motor task (finger tapping). The BOLD effect (red) is superimposed on structural T1-weighted images.

frontal gyrus. In previous MRIs, this patient did not show any abnormality.

Currently, there are two main approaches to improve image quality and spatial resolution of structural MRI: (1) the increase in field strength (3 and more Tesla machines) (Briellmann, Pell et al. 2003; Norris 2003) and (2) the use of phased array coils (Welker, Tsuruda et al. 2001). Preliminary reports demonstrate that the sensitivity of high-field MRI machines (3 and more Tesla) seems to be superior to the currently used 1.5t machines. These developments seem to promise further improvement of the sensitivity of the method for detecting individual pathology.

Functional magnetic resonance imaging

Functional magnetic resonance imaging (fMRI) is a well-established method that measures regional cerebral blood flow. The method is based on differences in signal intensity derived from oxygenated and deoxygenated hemoglobin (blood oxygen level dependent, BOLD) (Logothetis, Pauls et al. 2001). The synaptic activity of neurons causes an increase in regional cerebral blood flow. This increased supply of oxygenated hemoglobin exceeds the increased extraction of oxygen from the blood. Thus, the fraction of oxygenated hemoglobin is increased in areas of synaptic activity. By using repetitive block designs for specific tasks and averaging the repeated acquisitions, it is possible to identify specific changes in regional blood flow during a certain task. The two best-established applications are the identification of motor function and speech by adequate motor tasks (Figure 9) or speech-related tasks during the examination (Jack, Thompson et al. 1994; Binder, Swanson et al. 1996). These techniques are increasingly used to localize eloquent areas in patients being considered for resective epilepsy surgery and in whom the epileptogenic zones are adjacent to eloquent cortex. A relatively new approach is the visualization of oxygenation

changes related to interictal epileptiform activity. A single spike detected by scalp or invasive EEG results in an increased regional perfusion that can be depicted and localized by fMRI (Hoffmann, Jager et al. 2000; Jäger, Werhahn et al. 2002). Figure 10 shows a left temporal spike in scalp EEG and the corresponding regional hyperperfusion in the left lateral temporal lobe detected by fMRI. Functional MRI with simultaneous invasive and non-invasive EEG shows that the BOLD effect is more sensitive than non-invasive scalp EEG (Arnold, Weil et al. 2002). Epileptiform discharges recorded with invasive

electrodes were associated with a BOLD response even though the simultaneous scalp (non-invasive) EEG did not show any epileptiform discharges (Arnold, Weil et al. 2002). This preliminary finding most likely reflects the fact that a certain volume of cortex has to be involved in the generation

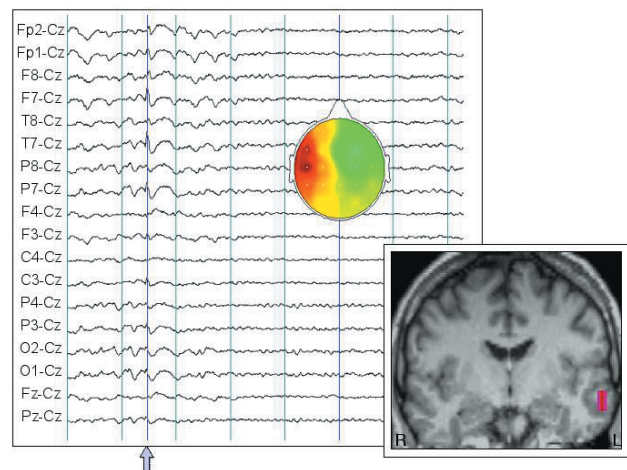


Figure 10. Functional MRI of spikes

Simultaneous EEG and MRI study. fMRI was triggered by a left temporal spike detected in scalp EEG. A circumscribed BOLD response (red) was measured in the left lateral temporal lobe, reflecting regional hyperperfusion induced by epileptiform discharge.

of the epileptiform discharge in order to be detected at the scalp EEG (Cooper, Winter et al. 1965).

Magnetic resonance spectroscopy

Magnetic resonance spectroscopy (MRS) allows the in vivo quantification of different cerebral metabolites. The most commonly used metabolites are N-acetyl-aspartate (NAA), a compound located only in neurons, and creatine (CR) and choline (CH), primarily found in glial cells (Urenjak, Williams et al. 1993). The intensity of NAA is comparable to that of CR and CH. Hence, neuronal loss or damage results in a reduced NAA level, whereas an increase in CR

and CH indicates gliosis. The spectroscopic pattern of a reduced ratio of NAA/CR-CH has a high sensitivity for the detection of epileptogenic foci. For temporal lobe epilepsy patients with known MTS, a reduced unilateral NAA/CR ratio on the side of EEG seizure onset could be identified in the majority of cases (Cendes, Andermann et al. 1994), but a linear correlation between the degree of NAA/CR-CH reduction and hippocampal volume loss measured by volumetry was not found (Kuzniecky, Hugg et al. 1998). This indicates that NAA/CR-CH reduction does not necessarily reflect neuronal loss, but is at least partially an effect of neuronal dysfunction, which precedes definite cell loss and volume reduction. This hypothesis is consistent with a recent study that identified widespread extratemporal pathologic MRS signals in temporal lobe epilepsy patients. NAA/CR-CH reduction was revealed in the ipsilateral insula, in both frontal lobes, and in the ipsilateral parietal lobe. For the frontal lobe, bilateral alterations were prominent in the mesial and anterior part, whereas the lateral frontal lobe only showed ipsilateral involvement (Mueller, Laxer et al. 2004). These findings correlate well with known pathways of seizure propagation from invasive EEG recordings (Adam, Saint-Hilaire et al. 1994) and with the alterations in glucose metabolism mentioned later in the PET section. So far, the majority of studies included patients with pathologies known from other modalities before MRS was performed. The number of patients in whom MRS reveals significant new information that is supplementary to other imaging modalities must still be determined.

Diffusion tensor imaging

Diffusion tensor imaging (DTI) is a new MRI technique, which visualizes the primary orientation of fiber tracks. First reports showed a disturbance of fiber coherence in the hippocampal formation in TLE patients (Assaf, Mohamed et al. 2003) or cortical dysplasia (Eriksson, Rugg-Gunn et al. 2001), which represents mild structural disorganization. Several case reports indicated that DTI revealed an area of histopathologically confirmed gliosis not visible in structural MRI, including FLAIR sequences (Assaf, Mohamed et al. 2003). However, the spatial resolution of DTI currently limits its application to displaying large fiber tracks, as they are often known from anatomy. This might be helpful when refining imaging in patients with a planned resection close to a relevant neuronal pathway, especially if the individual anatomy is disturbed by mass effects or malformations. DTI must still demonstrate its clinical value for the diagnostic evaluation of epilepsy patients.

Nuclear Medicine Imaging

Nuclear medicine methods are based on the detection of radiation, emitted from previously injected radiopharmaceuticals. Radioactive labeling of specific tracer molecules allows the qualitative and quantitative analysis of different physiological parameters such as glucose metabolism, regional cerebral perfusion, or the binding of ligands to specific receptors.

Positron-emission tomography

Positron-emission tomography uses positron-emitting radionuclides such as [18-F], [11-C], or [15-O] for the radioactive labeling of organic molecules. An emitted positron is immediately annihilated by its anti-part, an electron. The transformation of both particles from mass to energy results in two high-energy photons, emitted simultaneously in antiparallel directions. The scanner consists of a ring detector system that registers these photons. Since positron emission always results in two photons that appear simultaneously in opposite directions, it is easy to identify and exclude background radiation, which results in a higher spatial resolution than other nuclear medicine methods.

FDG-PET

Visualization of the cerebral glucose metabolism using [18-F]-fluoro-deoxy-glucose (FDG) is an established tool for localizing the epileptogenic region (Engel, Henry et al. 1990). Interictal epileptic dysfunction causes a suppressed physiological activity which results in regionally reduced metabolism. Consequently, regions of decreased glucose utilization were demonstrated in FDG-PET scans. Conversely, during a seizure the high synaptic activity of neurons results in an increased glucose metabolism in the epileptogenic region. To detect subclinical or clinical EEG seizure patterns that might influence the metabolism during the period of tracer distribution and FDG-PET image acquisition, it is necessary to record EEG during FDG-PET imaging.

The extent of the interictal metabolic alteration is typically much more widespread than the epileptogenic zone itself and often affects different lobes (Henry and Van Heertum 2003). Although the exact mechanism is not fully understood, this metabolic alteration in structurally normal tissue appears to be a dynamic marker of physiologic dysfunction associated with ongoing epileptic discharges (Rausch, Henry et al. 1994). The extratemporal hypometabolism observed in patients with left mesial temporal epilepsy corresponds to the neuropsychological deficits of these patients (Arnold, Schlaug et al. 1996). This functional

metabolic disturbance in remote areas is reversible after successful partial temporal resection (Hajek, Wieser et al. 1994; Spanaki, Kopylev et al. 2000) and correlates with clinical improvement of cognitive dysfunction (Martin, Sawrie et al. 2000). However, a positive correlation with the duration of epilepsy could be shown for mesiotemporal hypometabolism in temporal lobe epilepsy. Since this finding is consistent with the volume loss observed (Theodore, Bhatia et al. 1999), it indicates progressive neuronal damage in the mesiotemporal structures rather than only temporary dysfunction (Theodore, Kelley et al. 2004).

The sensitivity of FDG-PET for detecting unilateral temporal hypometabolism in patients with temporal lobe epilepsy is high: 84% for FDG-PET compared to 56% for MRI (Spencer 1994). However, a more recent meta-analysis summarized the results of 14 studies conducted after 1994: the average sensitivity was 86% for FDG-PET compared to 76% for MRI (Casse, Rowe et al. 2002). This reflects the advances in MRI which include increasing sensitivity for unilateral temporal pathologies, but it also emphasizes the diagnostic importance of FDG-PET. Unilateral temporal hypometabolism has been shown to be a major prognostic factor for determining the postoperative outcome after temporal lobe resection: unilateral hypometabolism was correlated with a higher rate of seizure-free outcome (Manno, Sperling et al. 1994; Blum, Ehsan et al. 1998; Casse, Rowe et al. 2002) and a reduced amount of postoperative cognitive deficits (Griffith, Perlman et al. 2000).

The sensitivity of FDG-PET is lower for extratemporal epilepsies, but it still has lateralizing value (Henry, Sutherland et al. 1991; Drzezga, Arnold et al. 1999). In young children with "catastrophic" epilepsies, epilepsy surgery relies more heavily on FDG-PET than in adults, because MRI and EEG reflect more diffuse pathology and are typically less localizing in children than in adults (Chugani, Shewmon et al. 1988; Chugani 1994).

Flumazenil-PET

Flumazenil is a reversible binding antagonist at the benzodiazepine binding site of GABA-A receptors. PET with [¹¹C]-labeled flumazenil is reported to reveal a reduced GABA-A receptor density in the epileptogenic region (Arnold, Berthele et al. 2000). There is evidence that the extent of flumazenil-PET abnormalities is more restricted to the epileptogenic region than FDG-PET abnormalities in temporal and extratemporal epilepsies (Pfluger, Weil et al. 1999; Arnold, Berthele et al. 2000; Juhasz, Chugani et al. 2000). Figure 11 shows a very circumscribed region of reduced

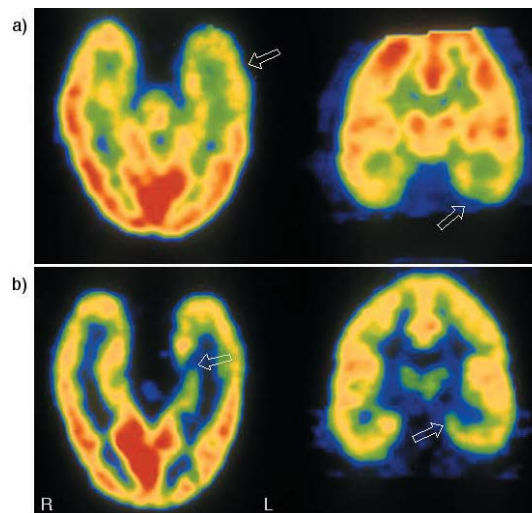


Figure 11. FDG- and Flumazenil-PET

The upper row (a) shows a transversal (upper left) and coronal (upper right) FDG-PET slice of a patient with left mesial temporal lobe epilepsy. FDG-PET shows an extensive hypometabolism in the entire temporal lobe compared to the contralateral side. The reduction of GABA-A receptor binding is restricted to the anterior part of the hippocampus (arrow) as documented by flumazenil-PET (lower row, b). Thus, flumazenil-PET reflects more restricted pathology in mesial temporal epilepsy than does FDG-PET.

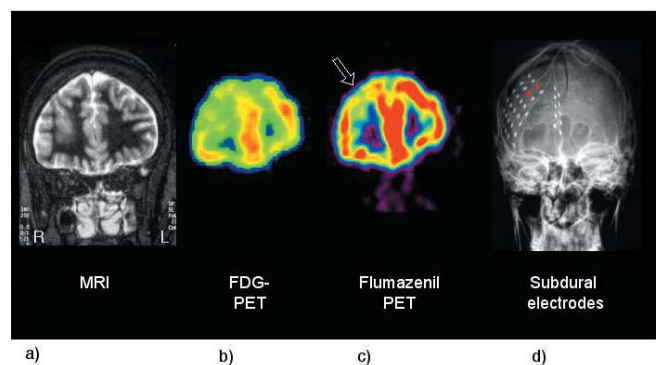


Figure 12. FDG- and Flumazenil-PET

(a) MRI shows cortical dysplasia in a patient with right frontal lobe epilepsy. (b) FDG-PET of this patient shows widespread hypometabolism in the right frontal lobe. (c) Flumazenil-PET in the same patient shows a more circumscribed reduction of GABA-A receptor binding (arrow). (d) The localization of flumazenil-PET abnormality was consistent with the seizure onset zone (red) identified by invasive EEG recordings with subdural electrodes (Arnold, Berthele et al. 2000).

GABA-A receptor binding restricted to the left temporomesial structures (Figure 11b) in a patient with mesial temporal lobe epilepsy. The FDG-PET, however, demonstrated a more widespread reduction of glucose metabolism (Figure 11a). Figure 12 shows corresponding MRI, FDG-PET, flumazenil-PET, and X-ray images of a patient with right frontal lobe epilepsy caused by focal cortical dysplasia. Again, the reduction of flumazenil binding is more circumscribed (arrow) than hypometabolism in FDG-PET. This was consistent with invasive EEG recordings which revealed seizure onset in the two red

subdural electrodes (Figure 12d) (Arnold, Berthele et al. 2000).

However, the sensitivity varies considerably between temporal and extratemporal epilepsies (Savic, Svanborg et al. 1996; Koepp, Richardson et al. 1997; Ryvlin, Bouvard et al. 1998; Juhasz, Chugani et al. 2000). The results range from 46% to 100%. More recent studies in patients with normal MRI showed additional focal increases in flumazenil binding in white matter, interpreted to be ectopic neurons in microdysgenesis (Hammers, Koepp et al. 2002; Hammers, Koepp et al. 2003). The rate of decreased flumazenil binding in temporal lobe epilepsies was only 33%. In the same study, less than half of the reported findings were consistent with clinical and interictal EEG data (Hammers, Koepp et al. 2002). The latter is consistent with our own experience based on invasive EEG studies and 3D localization of imaging findings with sensitivities below 40% for temporal and extratemporal epilepsies, combined with a high rate of false-positive findings (Vollmar, Arnold et al. 2003). Finally, the value of flumazenil-PET is still being evaluated and seems to be influenced by methodology to a certain degree.

Other PET Tracers

The many different PET tracers currently in use reflect different aspects of epileptogenicity. Tryptophane is the precursor for synthesis of serotonin, which is known to be elevated in dysplastic epileptogenic tissue (Trottier, Evrard et al. 1996). The analog alpha-methyl-L-tryptophan (AMT) labeled with [11C] has been used to identify the seizure onset zone in children with tuberous sclerosis (Asano, Chugani et al. 2000). In such cases an increased AMT uptake could differentiate between epileptogenic and non-epileptogenic tubers. Two other studies examining children with normal MRI or different malformations of cortical development (Fedi, Reutens et al. 2001; Juhasz, Chugani et al. 2003) reported areas of increased AMT uptake in 39%. Although the sensitivity was therefore lower than that of FDG-PET, the lesions detected were smaller than corresponding FDG-PET findings and had a higher specificity. Evidence from invasive EEG recordings showed that in the majority of patients the seizure onset zone was adjacent to the area of increased AMT uptake. Thus, AMT-PET can guide the implantation of subdural electrodes in nonlesional neocortical epilepsies.

Other tracers that have been used are [11C]-methionine, which has a high sensitivity for ganglioglioma, glioma (Maehara, Nariai et al. 2004), and focal cortical dysplasia (Sasaki, Kuwabara et al. 1998; Madakasira, Simkins et al.

2002), or [11C]-deuterium-deprenyl, as a marker for gliosis (Kumlien, Nilsson et al. 2001). Ligands to opioid receptors have been reported to reflect dynamic changes, following endogenous opioid release after seizures (Duncan 1997).

However, none of these tracers is currently available for routine clinical use. The availability of radiotracers depends on a cyclotron unit and associated radiochemistry, because of the short physical half-life of these radionuclides. The high cost is another limiting factor that restricts their application to scientific studies or selected patients.

Single photon emission computed tomography (SPECT)

Epileptic activity is associated with changes in regional cerebral blood flow that can be visualized with SPECT images. Usually, technetium-99m-labelled ethyl cysteinate dimer (ECD) or hexamethyl propylene aminoxime (HMPAO) are used as radiotracers. Both substances are characterized by their lipophilic molecular structure and high degree of diffusibility. This results in a high extraction rate from the blood pool during the first passage of capillary vessels. Once the tracer has passed the cellular membrane, enzymatic separation of the dimer leads to intracellular trapping. This fast tracer kinetic allows the visualization of regional cerebral blood flow at the time of tracer injection. During a seizure, the high synaptic activity causes an autoregulatory regional increase in perfusion (Uren, Magistretti et al. 1983) that can be visualized with ictal SPECT. Habitual seizures and electrically induced seizures with the same symptomatology caused identical patterns of hyperperfusion (Arnold, Noachtar et al. 2000).

The time of radiotracer injection is crucial, since in a very early stage of an epileptic seizure, maybe even before clinical onset, there may not be enough neurons involved to cause a visible increase of perfusion. Later in the course of the seizure, there is typically an increase of cerebral blood flow, which has a high localizing value in temporal lobe epilepsy and clearly differentiates between temporal and extratemporal epilepsies (Berkovic 1993; Won, Chang et al. 1999; Weil, Noachtar et al. 2001). The spread of epileptic activity is particularly rapid in extratemporal epilepsies. This reduces the localizing value of SPECT for frontal and occipital lobe epilepsies (Noachtar, Arnold et al. 1998; Arnold, Noachtar et al. 2000). Injection later than 100 seconds after seizure onset resulted in regional postictal hypoperfusion (Avery, Spencer et al. 1999). Consequently the effective acquisition of ictal SPECT images makes high logistic demands and is usually only possible during long-term video-EEG monitoring. EEG is needed to detect seizure

patterns early, and the radiotracer must be provided until a seizure occurs.

The sensitivity of ictal SPECT for detecting the seizure onset zone is reported to be in the range of 80% for temporal lobe epilepsy and up to 70% for extratemporal lobe epilepsies (Berkovic 1993; Won, Chang et al. 1999; Weil, Noachtar et al. 2001). One study compared the performance of the different perfusion tracers HMPAO and ECD and reported a higher sensitivity of HMPAO for TLE

(82% vs. 71%) and ETLE (70% vs. 29%) (Lee, Lee et al. 2002). This contradicts previous reports that ascribed a logistic and diagnostic superiority to ECD (O'Brien, Brinkmann et al. 1999).

A decline in the accuracy of SPECT localization was shown for temporal lobe epilepsy patients with frequent bilateral interictal epileptiform discharges (Velasco, Wichert-Ana et al. 2002). For patients with ambiguous findings in their first ictal SPECT study, repeated ictal SPECT imaging has been shown to be useful (Lee, Lee et al. 2002).

Similar to FGD-PET, interictal SPECT between seizures usually shows a corresponding hypoperfusion in the epileptogenic region, even though the sensitivity is lower than for ictal SPECT (Rowe, Berkovic et al. 1991). Subtraction of ictal and interictal SPECT allows the identification of specific changes in perfusion during the seizure and can increase the sensitivity and specificity of the examination up to 86% (Spanaki, Spencer et al. 1999). For better anatomic localization of results, the difference image can be superimposed on anatomic MRI images. This approach

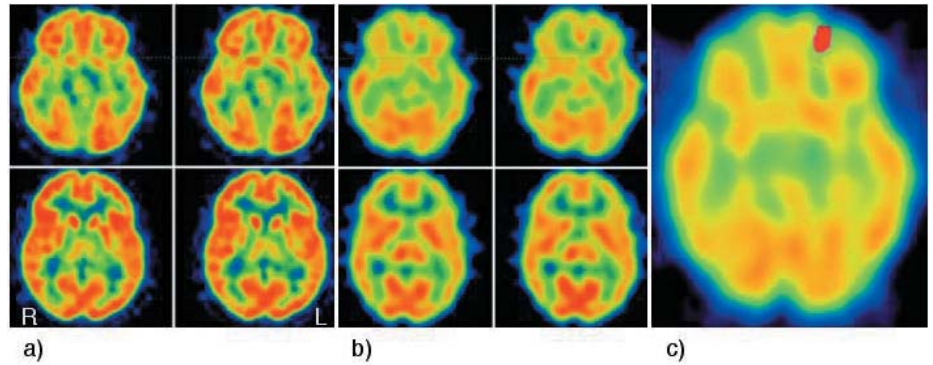


Figure 14. SPECT in extratemporal lobe epilepsies

Visual inspection of ictal (a) and interictal (b) ECD-SPECT images did not reveal any focal pathology. However, the subtraction image showed an ictal perfusion increase of more than 15% in the left frontopolar region (c; red spot overlaid on the interictal image).

of "Subtraction ictal SPECT co-registered to MRI" was described as SISCOM (O'Brien, So et al. 1998) and is an established part of the diagnostic evaluation in some epilepsy centers. In patients for whom no interictal SPECT scan is available, it is also possible to correlate the ictal SPECT with an interictal FDG-PET that shows a regional reduction of glucose metabolism, corresponding to the reduced interictal perfusion (Zubal, Avery et al. 2000). Figures 13 and 14 show examples of ictal, interictal, and subtracted ECD-SPECT in temporal (Figure 13) and frontal (Figure 14) lobe epilepsy. In the temporal lobe example, subtraction helped primarily to evaluate the extent of hyperperfusion. In the frontal lobe patient, visual inspection of the ictal and interictal scan did not reveal any focal abnormalities. However, subtraction of ictal and interictal images identified a regional increase in perfusion greater than 15% in the left frontopolar region. The area is marked with a red color overlay and superimposed on the interictal scan (Figure 14 c).

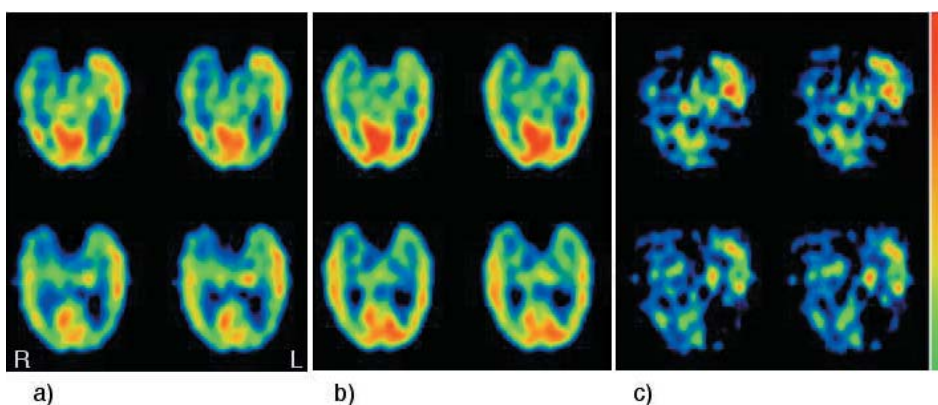


Figure 13. SPECT in temporal lobe epilepsies

This ictal ECD-SPECT scan (a) obtained during a habitual automotor seizure (Noachtar and Lüders 1997; Lüders, Acharya et al. 1998) and characterized by manual and oral automatisms in a patient with mesial temporal lobe epilepsy shows regional hyperperfusion in the left temporal neocortex. Subtraction from interictal images (b) enhances the region of hyperperfusion (c).

Image Post-Processing

Post-processing of image data can improve the sensitivity and specificity of imaging data in epilepsy patients. From the abundance of currently available image processing techniques, we will illustrate in the following two methods used routinely in the presurgical evaluation of epilepsy patients at the University of Munich Epilepsy Center: image co-registration and 3D reconstruction of the cortical surface (Figure 15).

Image co-registration allows the

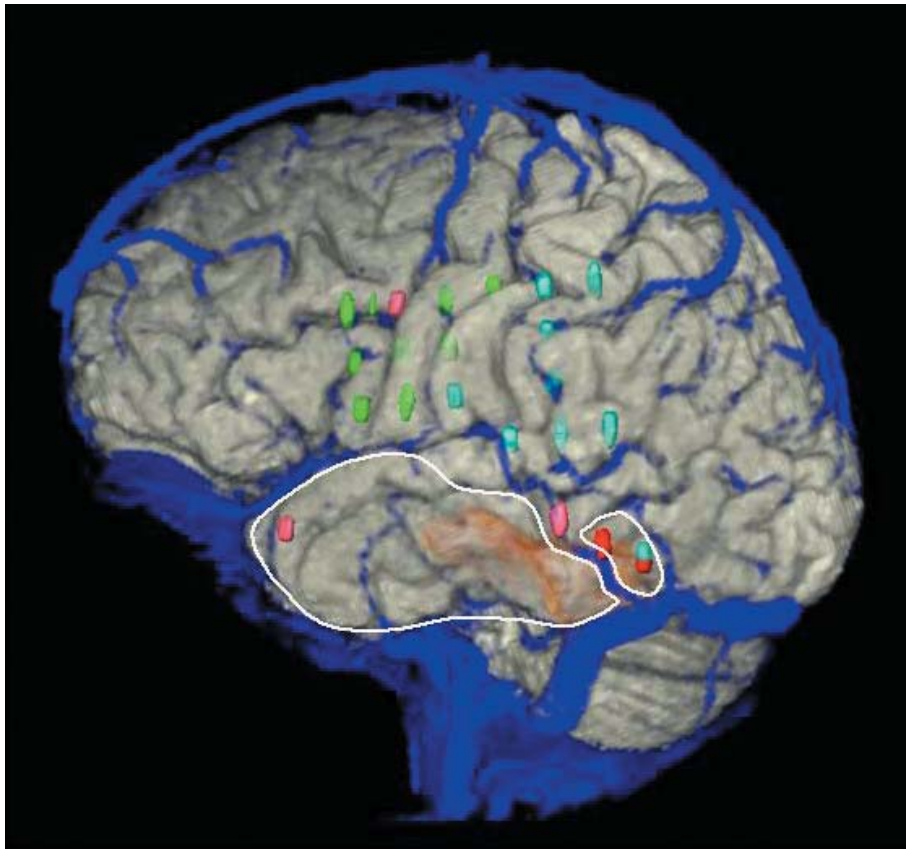


Figure 15. Image post-processing

3D reconstruction of the cortical relief from MRI and image registration allows the integrated visualization of cortical anatomy, the extent of post-traumatic gliosis (orange), the localization of the results obtained with subdural electrodes, and the individual anatomy of the cortical veins (blue). The results of invasive EEG-recording and cortical stimulation are color-coded: the seizure onset zone (red), area of maximum interictal spiking (pink), motor face response elicited by electrical stimulation of the cortex (green), speech areas (blue). The resection line is marked white. The seizure onset zone posterior to the prominent vein of Labbé was resected subpially. The resection of the speech area in the inferior temporal gyrus overlapping with the seizure onset zone caused only temporary mild impairment of speech function (Lüders, Lesser et al. 1986).

correlation of two different imaging modalities that provide complementary information. Typically a structural MRI showing the patient's individual anatomy is combined with functional modalities like PET, SPECT, or fMRI. To align two data sets to corresponding positions in three dimensions, a variety of automatic and manual methods are available which have been reviewed elsewhere (Hawkes 1998). Due to the reliability provided by an experienced user, we prefer interactive co-registration, which has been shown to achieve an accuracy of 1.5 mm (Pfluger, Vollmar et al. 2000). Image co-registration allows the precise localization of functional findings in the context of the patient's individual anatomy. This is particularly useful in patients with normal structural MRI and circumscribed findings in nuclear medicine studies.

3D reconstruction of high-resolution MRI allows both presurgical evaluation of the patient's cortical anatomy and detailed planning of each individual surgery.

Combination with image co-registration prior to 3D rendering permits the integration of information from several imaging modalities, e.g., the position of subdural electrodes identified from computed tomography (Winkler, Vollmar et al. 2000). Figure 15 shows an integrated 3D reconstruction from a patient with temporal lobe epilepsy, including MRI, CT, MR-venography, electrophysiological results, and the planned resection line in one image.

SUMMARY and CONCLUSION

Neuroimaging plays an essential role in the diagnosis of epilepsy patients, especially in the presurgical evaluation of patients with medically refractory focal epilepsies. Currently, MRI is the most important method for detecting epileptogenic lesions. The detection of mesial temporal sclerosis is crucial for the prognosis and the medical and surgical treatment options of temporal lobe epilepsy. The yield of MRI and other imaging methods such as PET and SPECT is lower for extratemporal lobe epilepsies. Since the introduction of functional imaging studies (PET and SPECT), less invasive evaluations have been performed in patients with

temporal lobe epilepsy, and those performed were more localized and restricted in extratemporal epilepsies. Due to continuous improvements new MRI techniques like MR spectroscopy and newly developed PET and SPECT tracers for functional imaging will probably be available for clinical use in the near future. The number of patients with structural or functional lesions identified by neuroimaging will continue to increase, allowing identification of specific etiologies and reducing invasive investigations. This will eventually lead to better therapeutic options that will hopefully improve the quality of life of our epilepsy patients.

REFERENCES

- Adam, C., J. M. Saint-Hilaire, et al. (1994). "Temporal and spatial characteristics of intracerebral seizure propagation: predictive value in surgery for temporal lobe epilepsy." *Epilepsia* 35(5): 1065-72.
- Arnold, S., A. Berthele, et al. (2000). "Reduction of benzodiazepine receptor binding is related to the seizure onset zone in extratemporal focal cortical

- dysplasia." *Epilepsia* 41(7): 818-24.
- Arnold, S., S. Noachtar, et al. (2000). "Ictal SPECT hyperperfusion reflects the activation of the symptomatogenic cortex in spontaneous and electrically-induced non-habitual focal epileptic seizures: correlation with subdural EEG recordings." *Epileptic Disord* 2(1): 41-4.
- Arnold, S., G. Schlaug, et al. (1996). "Topography of interictal glucose hypometabolism in unilateral mesiotemporal epilepsy." *Neurology* 46(5): 1422-1430.
- Arnold, S., G. Schlaug, et al. (1996). "Topography of interictal glucose hypometabolism in unilateral mesiotemporal epilepsy." *Neurology* 46(5): 1422-30.
- Arnold, S., S. Weil, et al. (2002). "Visualization of interictal spikes as measured with subdural EEG electrodes using functional magnetic imaging." *Epilepsia* 43(Suppl. 7): 87.
- Asano, E., D. C. Chugani, et al. (2000). "Multimodality imaging for improved detection of epileptogenic foci in tuberous sclerosis complex." *Neurology* 54(10): 1976-84.
- Assaf, B. A., F. B. Mohamed, et al. (2003). "Diffusion tensor imaging of the hippocampal formation in temporal lobe epilepsy." *AJNR Am J Neuroradiol* 24(9): 1857-62.
- Avery, R. A., S. S. Spencer, et al. (1999). "Effect of injection time on postictal SPET perfusion changes in medically refractory epilepsy." *Eur J Nucl Med* 26(8): 830-6.
- Bergin, P. S., D. R. Fish, et al. (1995). "Magnetic resonance imaging in partial epilepsy: additional abnormalities shown with the fluid attenuated inversion recovery (FLAIR) pulse sequence." *J Neurol Neurosurg Psychiatry* 58(4): 439-43.
- Berkovic, S. F. (1993). *Single photon emission tomography. Surgical Treatment of the Epilepsies* (ed 2). J. Engel. New York, Raven Press: 233-243.
- Berkovic, S. F., F. Andermann, et al. (1991). "Hippocampal sclerosis in temporal lobe epilepsy demonstrated by magnetic resonance imaging." *Ann Neurol* 29(2): 175-82.
- Bernasconi, A., V. Martinez, et al. (2001). "Surgical resection for intractable epilepsy in "double cortex" syndrome yields inadequate results." *Epilepsia* 42(9): 1124-9.
- Binder, J. R., S. J. Swanson, et al. (1996). "Determination of language dominance using functional MRI: a comparison with the Wada test." *Neurology* 46(4): 978-84.
- Blum, D. E., T. Ehsan, et al. (1998). "Bilateral temporal hypometabolism in epilepsy." *Epilepsia* 39(6): 651-9.
- Briellmann, R. S., G. S. Pell, et al. (2003). "MR imaging of epilepsy: state of the art at 1.5 T and potential of 3 T." *Epileptic Disord* 5(1): 3-20.
- Casse, R., C. C. Rowe, et al. (2002). "Positron emission tomography and epilepsy." *Mol Imaging Biol* 4(5): 338-51.
- Cendes, F., F. Andermann, et al. (1994). "Lateralization of temporal lobe epilepsy based on regional metabolic abnormalities in proton magnetic resonance spectroscopic images." *Ann Neurol* 35(2): 211-6.
- Cheon, J. E., K. H. Chang, et al. (1998). "MR of hippocampal sclerosis: comparison of qualitative and quantitative assessments." *AJNR Am J Neuroradiol* 19(3): 465-8.
- Chugani, H. T. (1994). "The role of PET in childhood epilepsy. [Review]." *Journal of Child Neurology* 9 Suppl 1: S82-8.
- Chugani, H. T., D. A. Shewmon, et al. (1988). "Surgical treatment of intractable neonatal-onset seizures: the role of positron emission tomography." *Neurology* 38(8): 1178-88.
- Cooper, R., A. L. Winter, et al. (1965). "Comparison of subcortical, cortical, and scalp activity using chronically indwelling electrodes in man." *Electroenceph Clin Neurophysiol* 18: 217-228.
- Diehl, B., I. Najm, et al. (2001). "Postictal diffusion-weighted imaging for the localization of focal epileptic areas in temporal lobe epilepsy." *Epilepsia* 42(1): 21-8.
- Drzezga, A., S. Arnold, et al. (1999). "18F-FDG PET studies in patients with extratemporal and temporal epilepsy: evaluation of an observer-independent analysis." *J Nucl Med* 40(5): 737-46.
- Duncan, J. S. (1997). "Imaging and epilepsy." *Brain* 120 (Pt 2): 339-77.
- Engel, J., Jr. (2002). "So what can we conclude—do seizures damage the brain?" *Prog Brain Res* 135: 509-12.
- Engel, J., Jr., T. R. Henry, et al. (1990). "Presurgical evaluation for partial epilepsy: relative contributions of chronic depth-electrode recordings versus FDG-PET and scalp-sphenoidal ictal EEG." *Neurology* 40(11): 1670-7.
- Eriksson, S. H., F. J. Rugg-Gunn, et al. (2001). "Diffusion tensor imaging in patients with epilepsy and malformations of cortical development." *Brain* 124(Pt 3): 617-26.
- Fedi, M., D. Reutens, et al. (2001). "Localizing value of alpha-methyl-L-tryptophan PET in intractable epilepsy of neocortical origin." *Neurology* 57(9): 1629-36.
- Garcia-Flores, E. (1994). "Surgical treatment of complex partial seizures: 20 years' experience." *Stereotact Funct Neurosurg* 62(1-4): 216-21.
- Griffith, H. R., S. B. Perlman, et al. (2000). "Preoperative FDG-PET temporal lobe hypometabolism and verbal memory after temporal lobectomy." *Neurology* 54(5): 1161-5.
- Hajek, M., H. G. Wieser, et al. (1994). "Preoperative and postoperative glucose consumption in mesiobasal and lateral temporal lobe epilepsy." *Neurology* 44(11): 2125-32.
- Hammers, A., M. J. Koepp, et al. (2002). "Abnormalities of grey and white matter [¹¹C]flumazenil binding in temporal lobe epilepsy with normal MRI." *Brain* 125(Pt 10): 2257-71.
- Hammers, A., M. J. Koepp, et al. (2003). "Grey and white matter flumazenil binding in neocortical epilepsy with normal MRI. A PET study of 44 patients." *Brain* 126(Pt 6): 1300-18.
- Hawkes, D. J. (1998). "Algorithms for radiological image registration and their clinical application." *J Anat* 193(Pt 3): 347-61.
- Henry, T. R., W. W. Sutherling, et al. (1991). "Interictal cerebral metabolism in partial epilepsies of neocortical origin." *Epilepsy Res* 10(2-3): 174-82.
- Henry, T. R. and R. L. Van Heertum (2003). "Positron emission tomography and single photon emission computed tomography in epilepsy care." *Semin Nucl Med* 33(2): 88-104.
- Hoffmann, A., L. Jager, et al. (2000). "Electroencephalography during functional echo-planar imaging: detection of epileptic spikes using post-processing methods." *Magn Reson Med* 44(5): 791-8.
- Jack, C. R., Jr., C. H. Rydberg, et al. (1996). "Mesial temporal sclerosis: diagnosis with fluid-attenuated inversion-recovery versus spin-echo MR imaging." *Radiology* 199(2): 367-73.
- Jack, C. R., Jr., R. M. Thompson, et al. (1994). "Sensory motor cortex: correlation of presurgical mapping with functional MR imaging and invasive cortical mapping." *Radiology* 190(1): 85-92.
- Jäger, L., K. J. Werhahn, et al. (2002). "Focal epileptiform activity in the brain: detection with spike-related functional MR imaging—preliminary results." *Radiology* 223(3): 860-9.
- Jensen, I. and L. Klinken (1976). "Temporal lobe epilepsy and neuropathology. Histological findings in resected temporal lobes correlated to surgical results and clinical aspects." *Acta Neurol Scand* 54(5): 391-414.
- Juhasz, C., D. C. Chugani, et al. (2003). "Alpha-methyl-L-tryptophan PET detects epileptogenic cortex in children with intractable epilepsy." *Neurology* 60(6): 960-8.
- Juhasz, C., D. C. Chugani, et al. (2000). "Electroclinical correlates of flumazenil and fluorodeoxyglucose PET abnormalities in lesional epilepsy." *Neurology* 55(6): 825-35.
- Kim, J. A., J. I. Chung, et al. (2001). "Transient MR signal changes in patients with generalized tonicoclonic seizure or status epilepticus: periictal diffusion-weighted imaging." *AJNR Am J Neuroradiol* 22(6): 1149-60.
- Koepp, M. J., M. P. Richardson, et al. (1997). "¹¹C-flumazenil PET, volumetric MRI, and quantitative pathology in mesial temporal lobe epilepsy." *Neurology*

- 49(3): 764-73.
- Kumlien, E., A. Nilsson, et al. (2001). "PET with 11C-deuterium-deprenyl and 18F-FDG in focal epilepsy." *Acta Neurol Scand* 103(6): 360-6.
- Kuzniecky, R., V. de la Sayette, et al. (1987). "Magnetic resonance imaging in temporal lobe epilepsy: pathological correlations." *Ann Neurol* 22(3): 341-7.
- Kuzniecky, R., J. W. Hugg, et al. (1998). "Relative utility of 1H spectroscopic imaging and hippocampal volumetry in the lateralization of mesial temporal lobe epilepsy." *Neurology* 51(1): 66-71.
- Kuzniecky, R. I. and R. C. Knowlton (2002). "Neuroimaging of epilepsy." *Semin Neurol* 22(3): 279-88.
- Lansberg, M. G., M. W. O'Brien, et al. (1999). "MRI abnormalities associated with partial status epilepticus." *Neurology* 52(5): 1021-7.
- Lee, D. H., F. Q. Gao, et al. (1998). "MR in temporal lobe epilepsy: analysis with pathologic confirmation." *AJNR Am J Neuroradiol* 19(1): 19-27.
- Lee, D. S., S. K. Lee, et al. (2002). "The usefulness of repeated ictal SPET for the localization of epileptogenic zones in intractable epilepsy." *Eur J Nucl Med Mol Imaging* 29(5): 607-14.
- Lee, D. S., S. K. Lee, et al. (2002). "Superiority of HMPAO ictal SPECT to ECD ictal SPECT in localizing the epileptogenic zone." *Epilepsia* 43(3): 263-9.
- Levesque, M. F., N. Nakasato, et al. (1991). "Surgical treatment of limbic epilepsy associated with extrahippocampal lesions: the problem of dual pathology." *J Neurosurg* 75(3): 364-70.
- Logothetis, N. K., J. Pauls, et al. (2001). "Neurophysiological investigation of the basis of the fMRI signal." *Nature* 412(6843): 150-7.
- Lüders, H., J. Acharya, et al. (1998). "Semiological seizure classification." *Epilepsia* 39(9): 1006-1013.
- Lüders, H., R. P. Lesser, et al. (1986). "Basal temporal language area demonstrated by electrical stimulation." *Neurology* 36(4): 505-510.
- Lüders, H. O. and I. A. Awad (1992). *Conceptual considerations. Epilepsy surgery.* H. O. Lüders. New York, Raven Press: 51-62.
- Madakasira, P. V., R. Simkins, et al. (2002). "Cortical dysplasia localized by [11C]methionine positron emission tomography: case report." *AJNR Am J Neuroradiol* 23(5): 844-6.
- Maehara, T., T. Nariai, et al. (2004). "Usefulness of [11C]methionine PET in the diagnosis of dysembryoplastic neuroepithelial tumor with temporal lobe epilepsy." *Epilepsia* 45(1): 41-5.
- Manno, E. M., M. R. Sperling, et al. (1994). "Predictors of outcome after anterior temporal lobectomy: positron emission tomography." *Neurology* 44(12): 2331-6.
- Margerison, J. H. and J. A. Corsellis (1966). "Epilepsy and the temporal lobes. A clinical, electroencephalographic and neuropathological study of the brain in epilepsy, with particular reference to the temporal lobes." *Brain* 89(3): 499-530.
- Martin, R. C., S. M. Sawrie, et al. (2000). "Investigation of executive function change following anterior temporal lobectomy: selective normalization of verbal fluency." *Neuropsychology* 14(4): 501-8.
- Mueller, S. G., K. D. Laxer, et al. (2004). "Identification of abnormal neuronal metabolism outside the seizure focus in temporal lobe epilepsy." *Epilepsia* 45(4): 355-66.
- Noachtar, S., S. Arnold, et al. (1998). "Ictal technetium-99m ethyl cysteinate dimer single-photon emission tomographic findings and propagation of epileptic seizure activity in patients with extratemporal epilepsies." *Eur J Nucl Med* 25(2): 166-72.
- Noachtar, S. and H. O. Lüders (1997). *Classification of epileptic seizures and epileptic syndromes. Textbook of stereotactic and functional neurosurgery.* P. L. Gildenberg and R. R. Taxer. New York, McGraw-Hill: 1763-1774.
- Noachtar, S., P. A. Winkler, et al. (2003). *Surgical therapy of epilepsy. Neurological disorders: course and treatment.* T. Brandt, C. Caplan, J. Dichgans, J. Diener and C. Kennard. San Diego, Academic Press: 235-244.
- Norris, D. G. (2003). "High field human imaging." *J Magn Reson Imaging* 18(5): 519-29.
- O'Brien, T. J., B. H. Brinkmann, et al. (1999). "Comparative study of 99mTc-ECD and 99mTc-HMPAO for peri-ictal SPECT: qualitative and quantitative analysis." *J Neurol Neurosurg Psychiatry* 66(3): 331-9.
- O'Brien, T. J., E. L. So, et al. (1998). "Subtraction ictal SPECT co-registered to MRI improves clinical usefulness of SPECT in localizing the surgical seizure focus." *Neurology* 50(2): 445-54.
- Pfluger, T., C. Vollmar, et al. (2000). "Quantitative comparison of automatic and interactive methods for MRI-SPECT image registration of the brain based on 3-dimensional calculation of error." *J Nucl Med* 41(11): 1823-9.
- Pfluger, T., S. Weil, et al. (1999). "Normative volumetric data of the developing hippocampus in children based on magnetic resonance imaging." *Epilepsia* 40(4): 414-23.
- Rausch, R., T. R. Henry, et al. (1994). "Asymmetric interictal glucose hypometabolism and cognitive performance in epileptic patients." *Arch Neurol* 51(2): 139-44.
- Risinger, M. W., J. Engel, Jr., et al. (1989). "Ictal localization of temporal lobe seizures with scalp/sphenoidal recordings." *Neurology* 39(10): 1288-93.
- Robitaille, Y., T. Rasmussen, et al. (1992). "Histopathology of nonneoplastic lesions in frontal lobe epilepsy. Review of 180 cases with recent MRI and PET correlations." *Adv Neurol* 57: 499-513.
- Rogachewski, E., S. Mazer, et al. (1998). "[Visual and volumetric analysis with magnetic resonance of hippocampus formations in a group of patients with clinical diagnosis of temporal lobe epilepsy]." *Arq Neuropsiquiatr* 56(3A): 419-28.
- Rosenow, F. and H. Lüders (2001). "Presurgical evaluation of epilepsy." *Brain* 124(Pt 9): 1683-700.
- Rowe, C. C., S. F. Berkovic, et al. (1991). "Visual and quantitative analysis of interictal SPECT with technetium-99m-HMPAO in temporal lobe epilepsy." *J Nucl Med* 32(9): 1688-94.
- Ryvlin, P., S. Bouvard, et al. (1998). "Clinical utility of flumazenil-PET versus [18F]fluorodeoxyglucose-PET and MRI in refractory partial epilepsy. A prospective study in 100 patients." *Brain* 121 (Pt 11): 2067-81.
- Sasaki, M., Y. Kuwabara, et al. (1998). "Carbon-11-methionine PET in focal cortical dysplasia: a comparison with fluorine-18-FDG PET and technetium-99m-ECD SPECT." *J Nucl Med* 39(6): 974-7.
- Savic, I., E. Svanborg, et al. (1996). "Cortical benzodiazepine receptor changes are related to frequency of partial seizures: a positron emission tomography study." *Epilepsia* 37(3): 236-44.
- Schulz, R., H. O. Lüders, et al. (2000). "Interictal EEG and ictal scalp EEG propagation are highly predictive of surgical outcome in mesial temporal lobe epilepsy." *Epilepsia* 41(5): 564-70.
- Siegel, A. M., B. C. Jobst, et al. (2001). "Medically intractable, localization-related epilepsy with normal MRI: presurgical evaluation and surgical outcome in 43 patients." *Epilepsia* 42(7): 883-8.
- Spanaki, M. V., L. Kopylev, et al. (2000). "Postoperative changes in cerebral metabolism in temporal lobe epilepsy." *Arch Neurol* 57(10): 1447-52.
- Spanaki, M. V., S. S. Spencer, et al. (1999). "Sensitivity and specificity of quantitative difference SPECT analysis in seizure localization." *J Nucl Med* 40(5): 730-6.
- Spencer, S. S. (1994). "The relative contributions of MRI, SPECT, and PET imaging in epilepsy." *Epilepsia* 35 Suppl 6: S72-89.
- Sperling, M. R., M. J. O'Connor, et al. (1992). "A noninvasive protocol for anterior temporal lobectomy." *Neurology* 42(2): 416-422.
- Stefan, H., C. Hummel, et al. (2003). "Magnetic brain source imaging of focal epileptic activity: a synopsis of 455 cases." *Brain* 126(Pt 11): 2396-405.
- Theodore, W. H., S. Bhatia, et al. (1999). "Hippocampal atrophy, epilepsy duration, and febrile seizures in patients with partial seizures." *Neurology* 52(1): 132-6.
- Theodore, W. H., K. Kelley, et al. (2004). "Epilepsy duration, febrile seizures, and cerebral glucose metabolism." *Epilepsia* 45(3): 276-9.
- Trottier, S., B. Evrard, et al. (1996). "The serotonergic innervation of the cerebral cortex in man and its changes in focal cortical dysplasia." *Epilepsy Res* 25(2): 79-106.

- Tuxhorn, I., H. Holthausen, et al. (1994). "Reversible cortical oedema mimicking cortical dysplasia in mitochondrial disorder." *J Neurol Neurosurg Psychiatry* 57(11): 1439.
- Uren, R. F., P. L. Magistretti, et al. (1983). "Single-photon emission computed tomography. A method of measuring cerebral blood flow in three dimensions (preliminary results of studies in patients with epilepsy and stroke)." *Med J Aust* 1(9): 411-3.
- Urenjak, J., S. R. Williams, et al. (1993). "Proton nuclear magnetic resonance spectroscopy unambiguously identifies different neural cell types." *J Neurosci* 13(3): 981-9.
- Van Buren, J. M. (1987). *Complications of surgical procedures in the diagnosis and treatment of epilepsy. Surgical treatment of the epilepsies.* J. J. Engel. New York, Raven Press: 465-475.
- Velasco, T. R., L. Wichert-Ana, et al. (2002). "Accuracy of ictal SPECT in mesial temporal lobe epilepsy with bilateral interictal spikes." *Neurology* 59(2): 266-71.
- Vollmar, C., S. Arnold, et al. (2003). "Flumazenil PET versus intracranial EEG for localization of temporal and extratemporal seizure onset zone in adult." *Epilepsia* 44, Suppl. 9: 82.
- Von Oertzen, J., H. Urbach, et al. (2002). "Standard magnetic resonance imaging is inadequate for patients with refractory focal epilepsy." *J Neurol Neurosurg Psychiatry* 73(6): 643-7.
- Weil, S., S. Noachtar, et al. (2001). "Ictal ECD-SPECT differentiates between temporal and extratemporal epilepsy: confirmation by excellent postoperative seizure control." *Nucl Med Commun* 22(2): 233-7.
- Welker, K. M., J. S. Tsuruda, et al. (2001). "Radio-frequency coil selection for MR imaging of the brain and skull base." *Radiology* 221(1): 11-25.
- Wiesmann, U. C., G. J. Barker, et al. (1998). "Fast fluid-attenuated inversion-recovery imaging: first experience with a 3D version in epilepsy." *Neuroradiology* 40(8): 483-9.
- Winkler, P. A., C. Herzog, et al. (1999). "[Noninvasive protocol for surgical treatment of focal epilepsies]." *Nervenarzt* 70(12): 1088-93.
- Winkler, P. A., C. Vollmar, et al. (2000). "Usefulness of 3-D reconstructed images of the human cerebral cortex for localization of subdural electrodes in epilepsy surgery." *Epilepsy Res* 41(2): 169-78.
- Won, H. J., K. H. Chang, et al. (1999). "Comparison of MR imaging with PET and ictal SPECT in 118 patients with intractable epilepsy." *AJNR Am J Neuroradiol* 20(4): 593-9.
- Zubal, I. G., R. A. Avery, et al. (2000). "Ratio-images calculated from interictal positron emission tomography and single-photon emission computed tomography for quantification of the uncoupling of brain metabolism and perfusion in epilepsy." *Epilepsia* 41(12): 1560-6.

* *Yazarların isteği üzerine kaynak düzenlendiği biçimde yer almıştır. References published as requested by the authors.*

Curriculum Vitae Soheyl Noachtar

Dept. of Neurology
University of Munich
Marchioninstr. 15
81377 Munich / Germany
Phone: +49-89-70 95 3691
Fax: +49-89-70 95 6691
Email: noa@nro.med.uni-muenchen.de

Date of Birth: 15. Februar 1956

Place of Birth: Teheran/Iran

Citizenship: German

Education:

- Hermann Hedenus Grundschule Erlangen 1961-65
- Gymnasium Fridericianum Erlangen, Germany 1965-69
- Erich-Hoepner-Gymnasium West-Berlin/Germany 1969-73
- Freie Universität Berlin Medical School/Germany 1974-81

Degrees & Diplomas:

- M.D., Freie Universität Berlin/Germany 1981
- Dissertation in Epileptology, Freie Universität Berlin/Germany 1985
- Accreditation in Neurology and Psychiatry 1987
- American Board of Clinical Neurophysiology 1991
- Certificate "Epileptology" of the German Section of the International League against Epilepsy 1992
- Habilitation in Neurology, University of Munich, Munich/Germany 1999

Appointments:

- Residency in Internal and Psychosomatic Medicine, Fachklinik Hochsauerland, Schmalleberg/Germany
Residency in Psychiatry, Krankenhaus Havelhöhe, Berlin/Germany 1981-83
- Residency in Neurology, University of Witten-Herdecke/Germany 1983-85
- Senior Registrar, Dep. of Neurology, University of Witten-Herdecke/Germany 1985-87
- Fellow in Clinical Neurophysiology and Epilepsy, Dep. of Neurology, Cleveland Clinic Foundation, Cleveland, Ohio, USA 1987-89
- Head EEG, Bethel Epilepsy Center, Bielefeld/Germany 1989-91
- Lecturer in Clinical Neurophysiology, University of Witten-Herdecke/Germany 1991-94
- Head, Comprehensive Epilepsy Program/ EEG / Sleep lab, Dep. of Neurology, University of Munich, Munich/Germany since 1994
- Associate Professor of Neurology, University of Munich since 1994

Societies, Commission and Boards:

Editorial Board

- Epilepsia
- Epileptic Disorder (Video Section Editor)

Reviewer for Journals

- Brain
- Neurology
- Epilepsia
- Epileptic Disorders
- J Neurology
- Nervenarzt
- Der Anästhesist
- Experimental Brain Research
- Neurosurgical Review

Research Councils

- Research Council of the University of Munich
- German Research Council (Deutsche Forschungsgemeinschaft)

Commissions

- 1991 Lecturer and Examiner in EEG of the German Society of Clinical Neurophysiology (DGKN)
- 1995 Lecturer and Examiner in Evoked Potentials of the German Society of Clinical Neurophysiology (DGKN)
- 1996 Member of the EEG Commission of the German Society of Clinical Neurophysiology (DGKN)
- 1997 Reviewer in Neurology at the German Federal Institute for Drugs (Bundesinstitut für Medizinprodukte und Arzneimittel [BfArM])
- 2001 Director of EEG Teaching Programm for the German Society of Clinical Neurophysiology (DGKN)
- 2001 Lecturer and Examiner in Polysomnography of the German Society of Clinical Neurophysiology (DGKN)
- 2002 Director of the Commission „Definition of Epilepsy Centers“ of the German Section of the International League Against Epilepsy
- 2003 Member of the Drug Commission of the University of Munich
- 2003 Member of the scientific board of the German Epilepsy Surgery Society
- 1985 German Section of the International League Against Epilepsy
- 1989 Deutsche Gesellschaft für klinische Neurophysiologie (DGKN)
- 1991 American Board of Clinical Neurophysiology
- 1991 Founding member German Epilepsy Surgery Society
- 1994 German Neurological Society
- 1995 American Epilepsy Society (AES)
- 1995 European Neurological Society (ENS)
- 1996 German Sleep Society
- 2003 Honorary member of the Chilean Epilepsy Society (elected at the 50. Anniversary Meeting)